



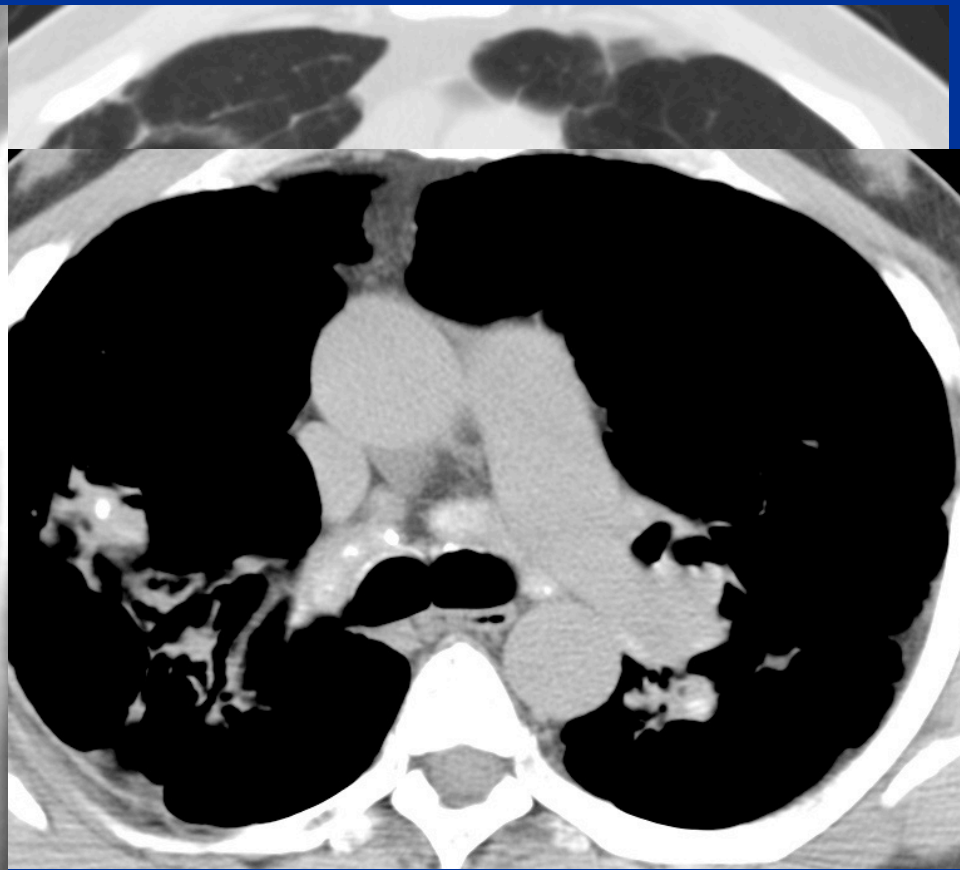
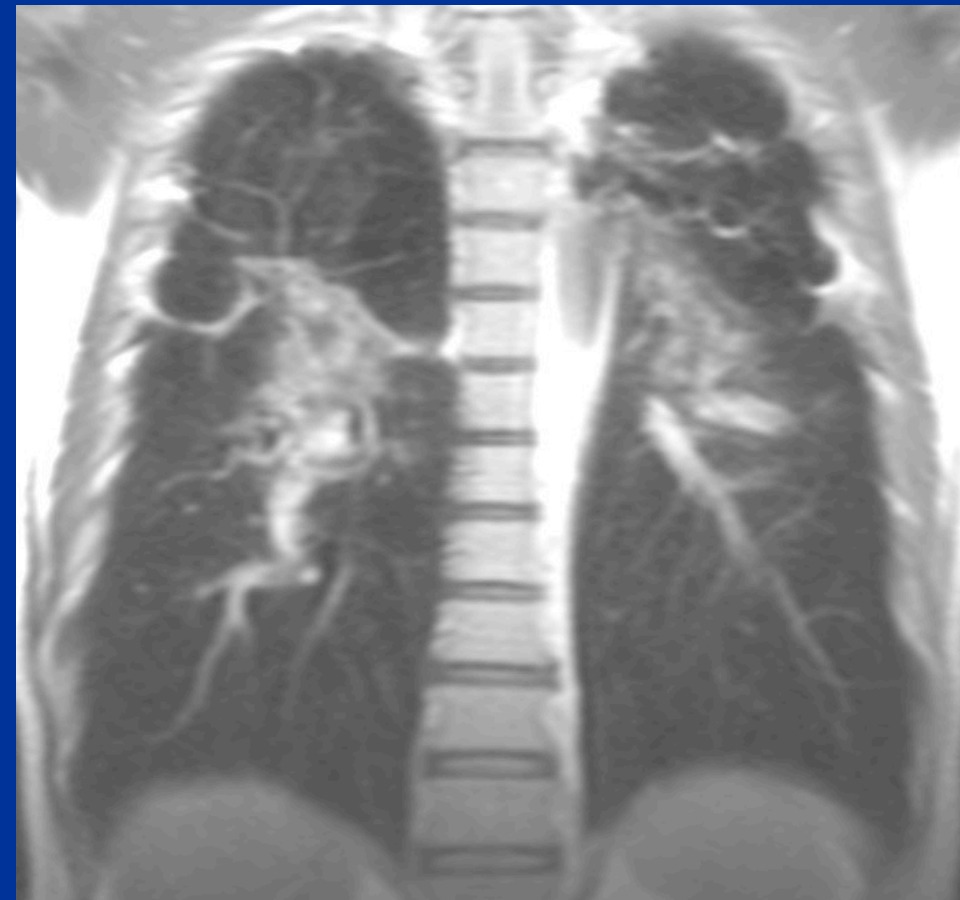
# Case Review: ILD

**Jonathan H. Chung, MD**  
**Professor of Radiology**  
**Vice Chair of Quality**  
**Section Chief, Cardiopulmonary Imaging**



AT THE FOREFRONT  
**UChicago**  
**Medicine**

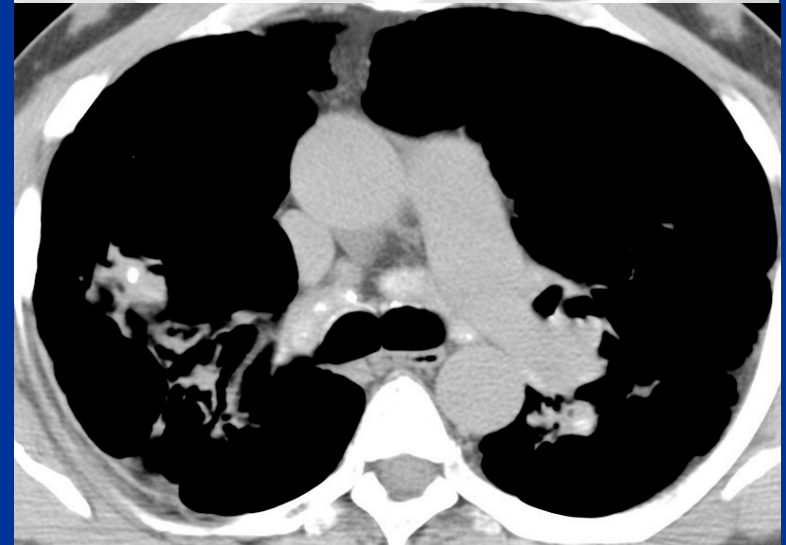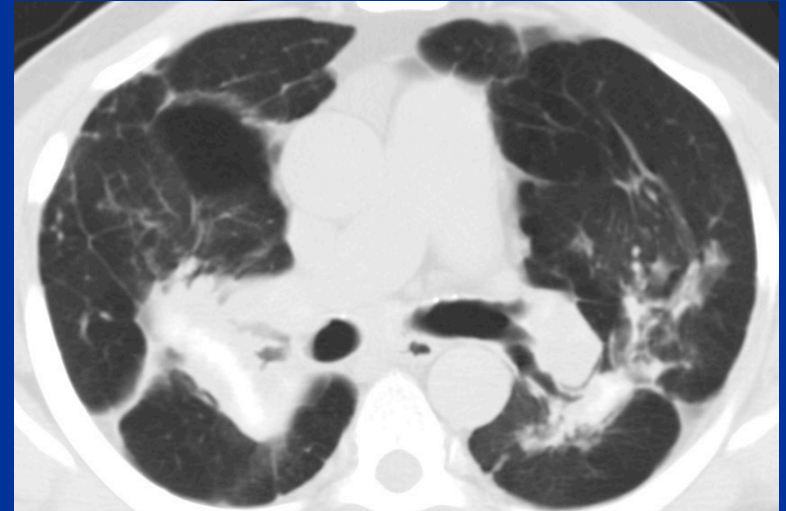
# Case 1 History



# Case 1

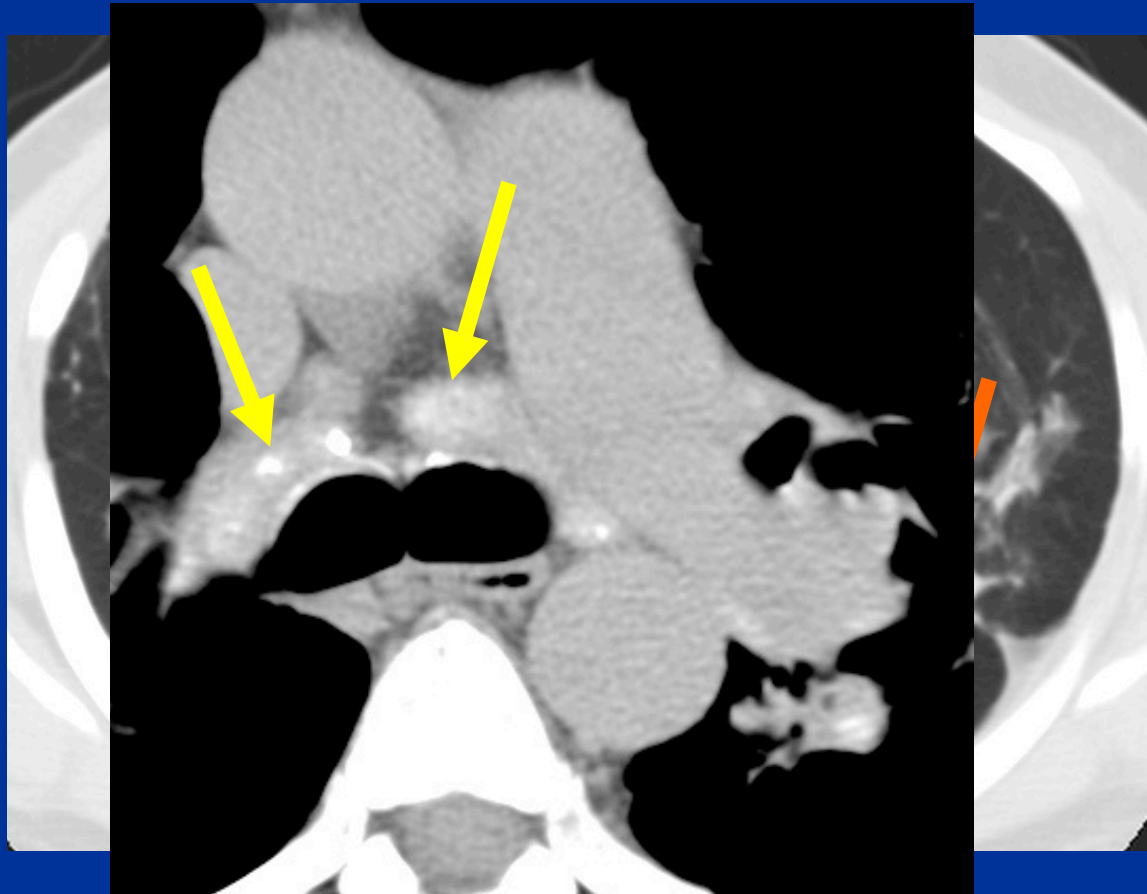
## What is the best diagnosis?

1. Cystic fibrosis
2. Hypersensitivity pneumonitis
3. Radiation-related fibrosis
4. Sarcoidosis



# Case 1 Findings

- Upper lung mass-like fibrosis
- Calcified mediastinal lymph nodes

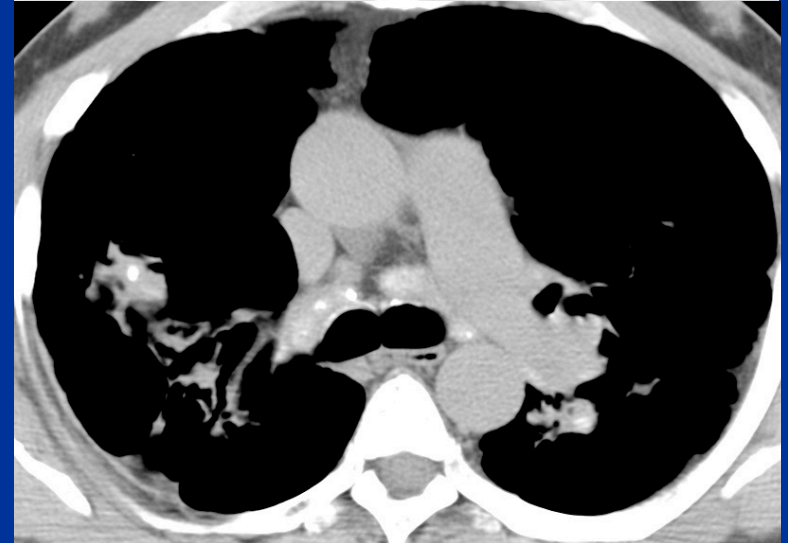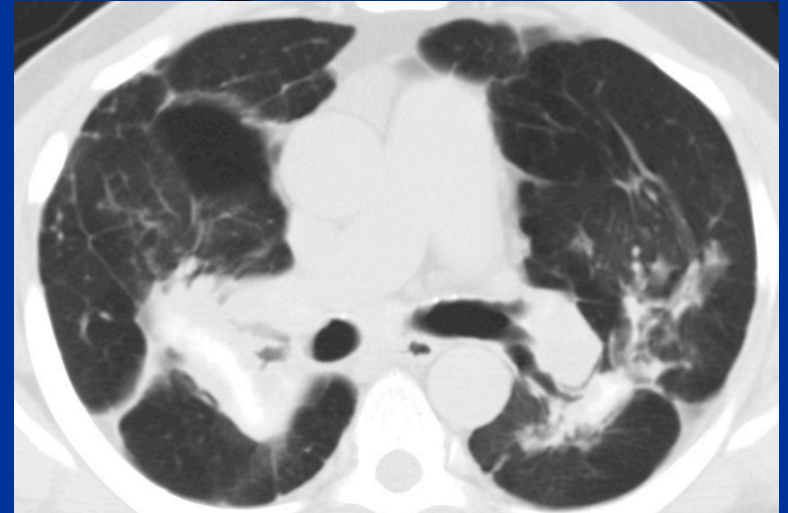




# Case 1

## What is the best diagnosis?

1. Cystic fibrosis
2. Hypersensitivity pneumonitis
3. Radiation-related fibrosis
4. Sarcoidosis



# Case 1 Differential Diagnosis

## Mass-like fibrosis

1. Radiation-related fibrosis
2. Sarcoidosis
3. Silicosis/Coal Worker's
4. Talcosis

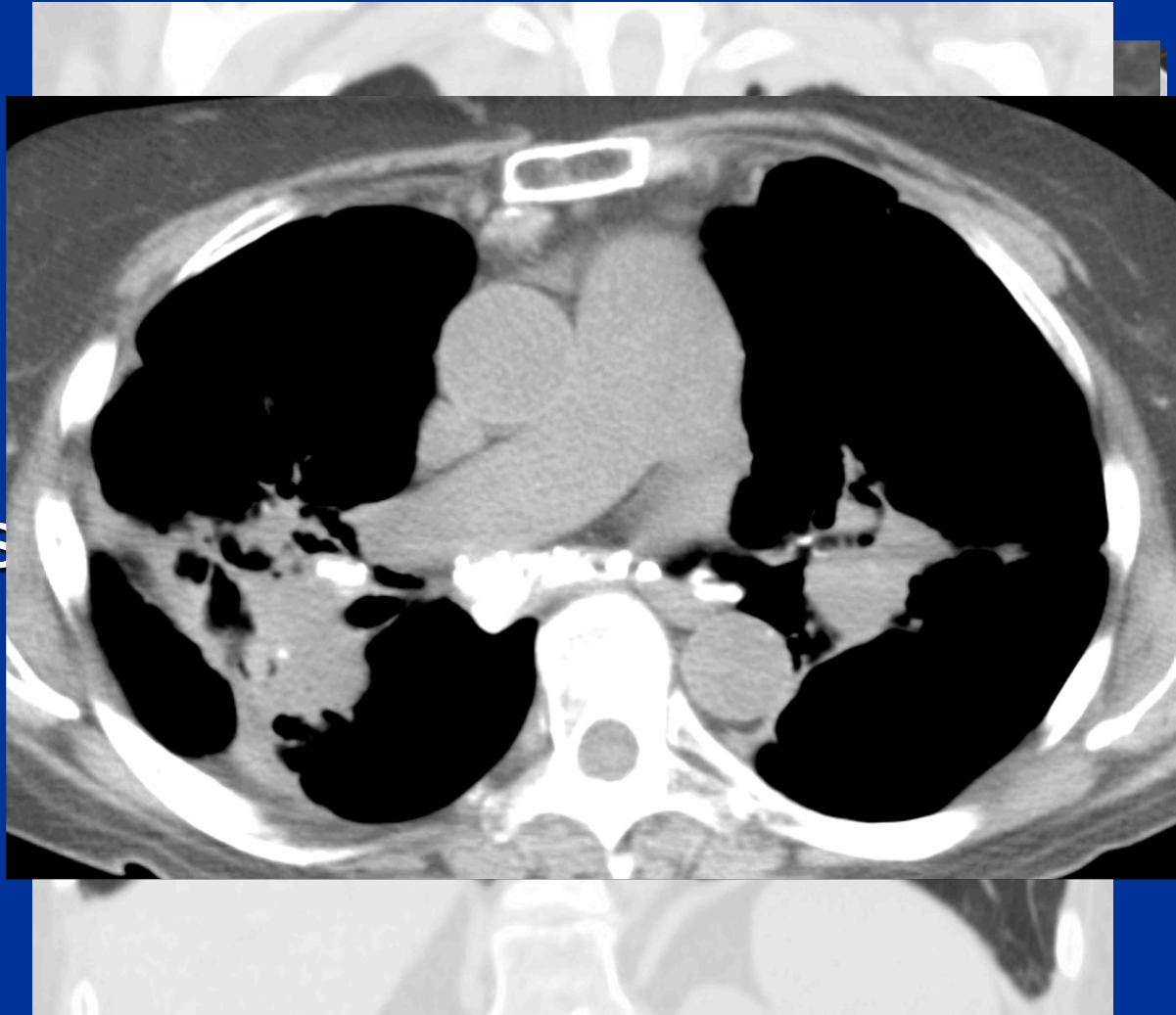
# Case 1 Differential Diagnosis

## Mass-like fibrosis

1. Radiation-related fibrosis
2. Sarcoidosis
3. Silicosis/Coal Worker's
4. Talcosis

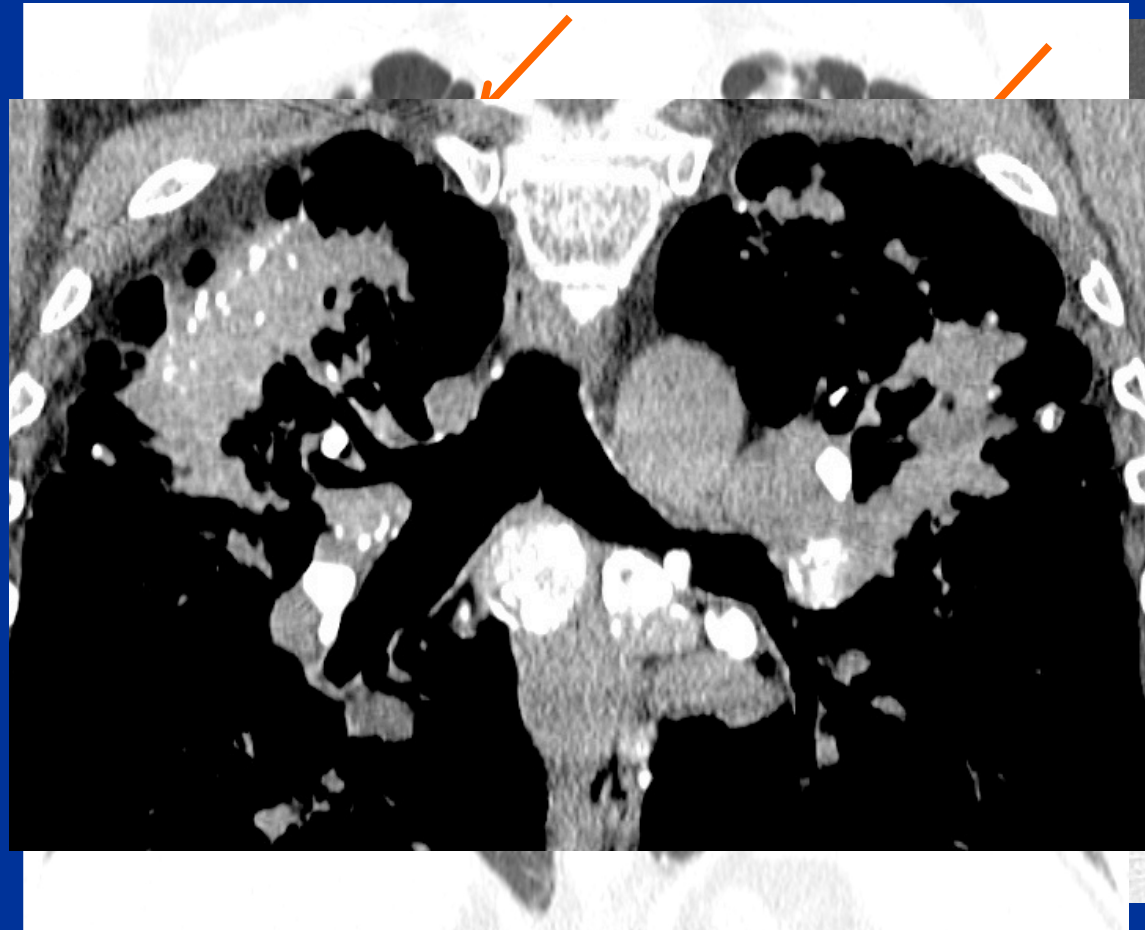
# Case 1 Differential Sarcoidosis

- Upper lung perilymphatic nodules
  - Interlobular
  - Peribronchial
- Upper lung fibrosis
  - Coalescent masses
- LAN (Ca<sup>2+</sup>)

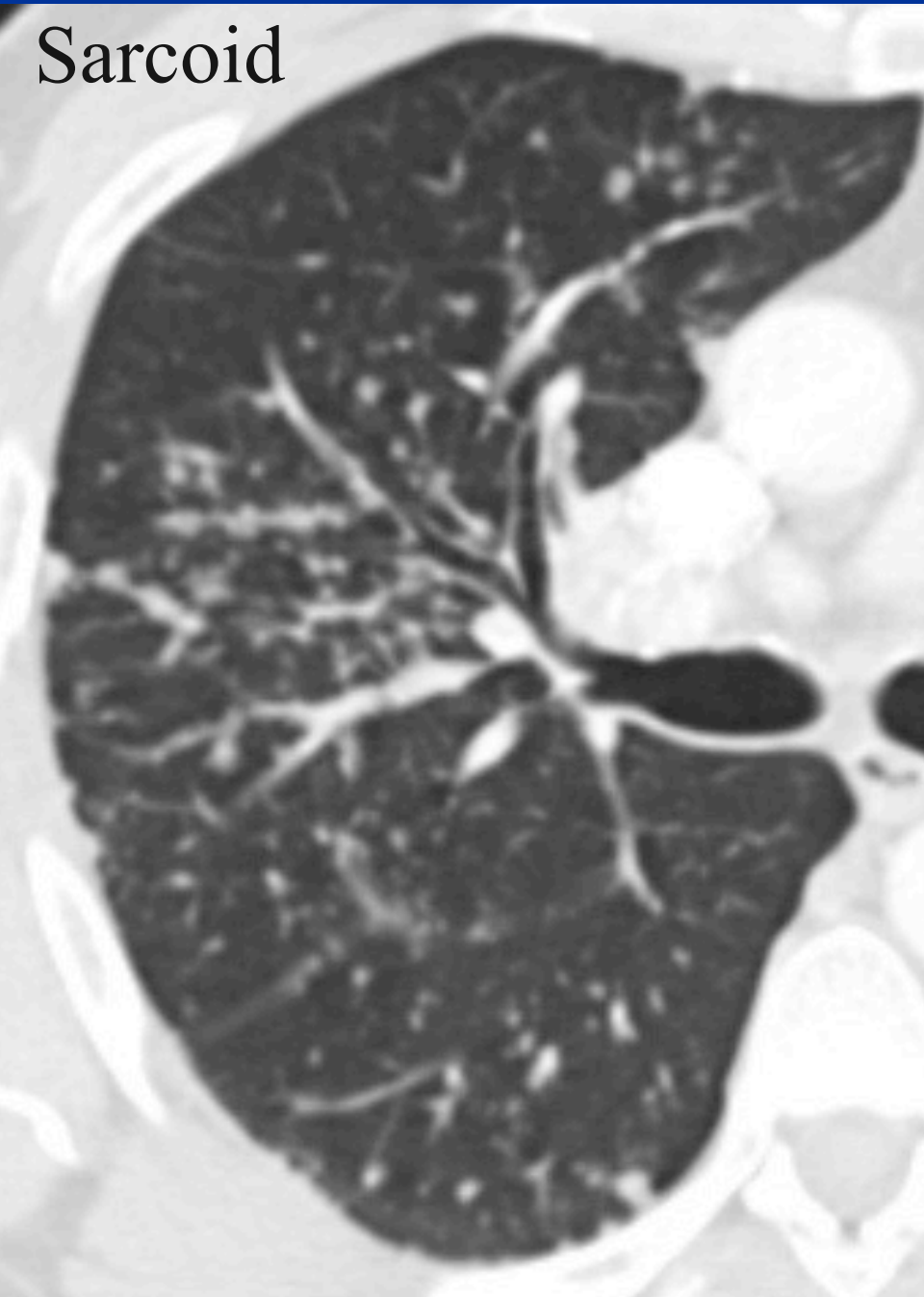


# Case 1 Differential Silicosis/CWP

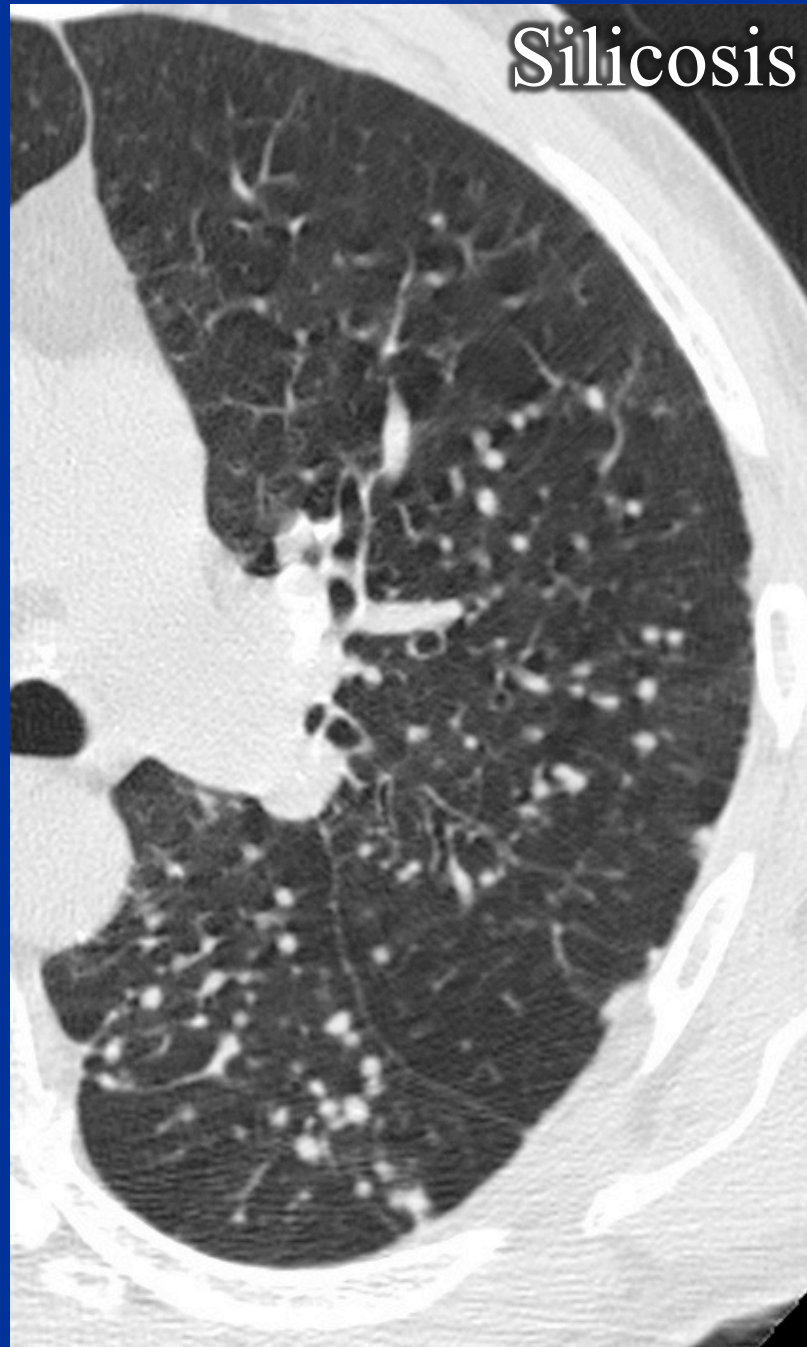
- Upper lung subpleural and centrilobular nodules
- PMF
- Paracatricial emphysema
- LAN



Sarcoid



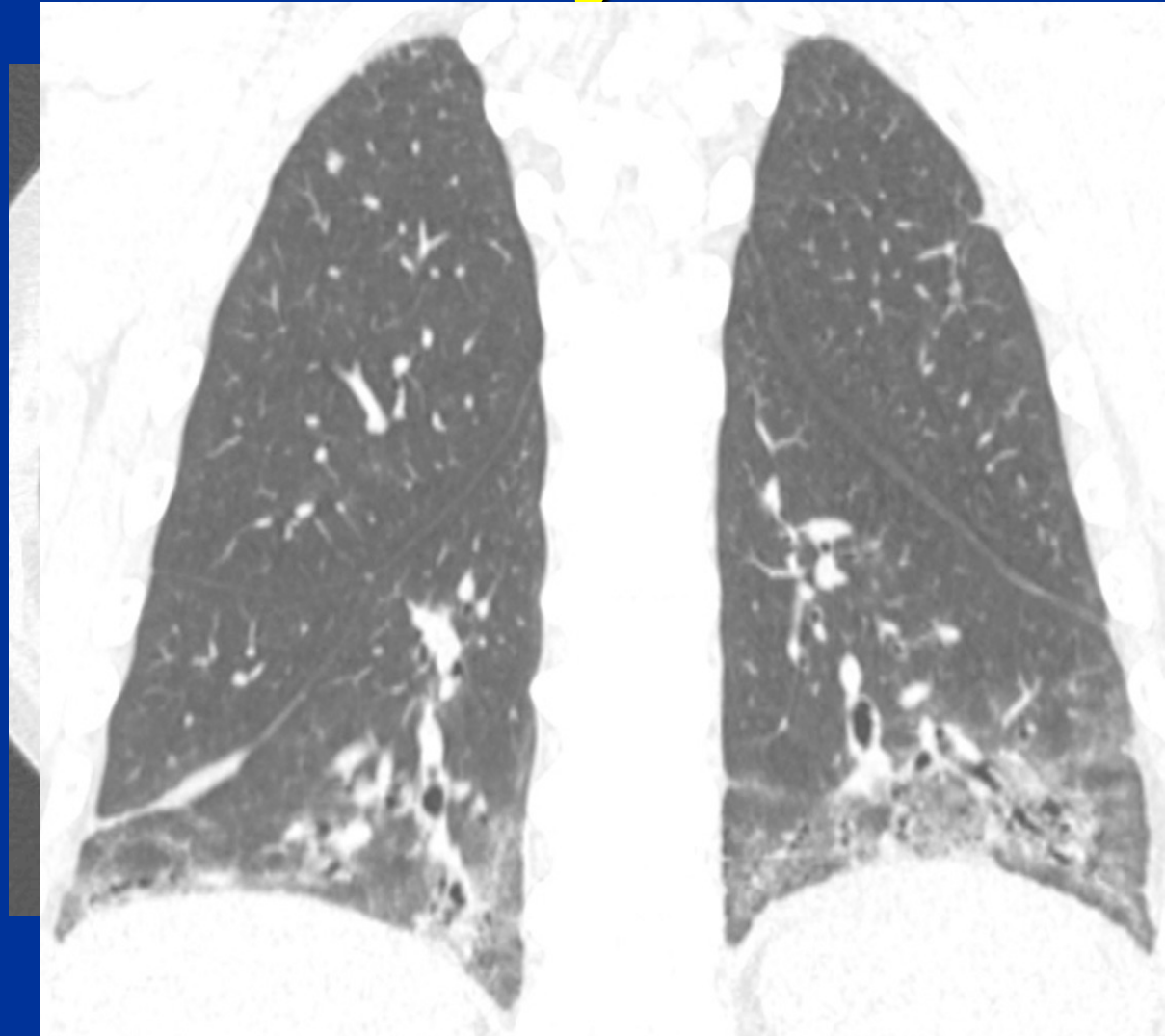
Silicosis





# Case 2 History

- 46-year-old man with abnormal radiographic findings

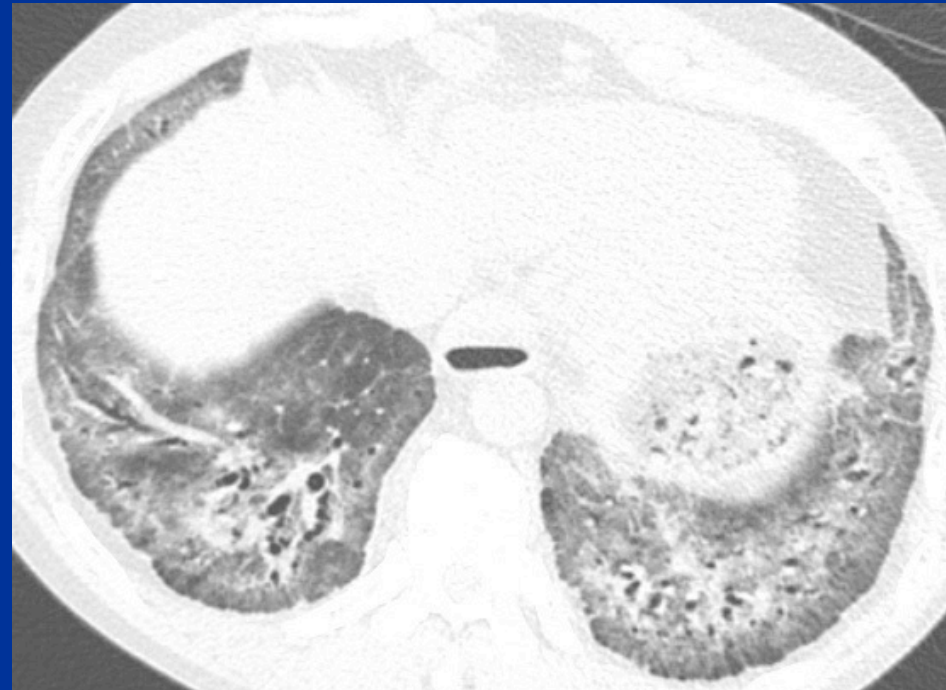




# Case 2

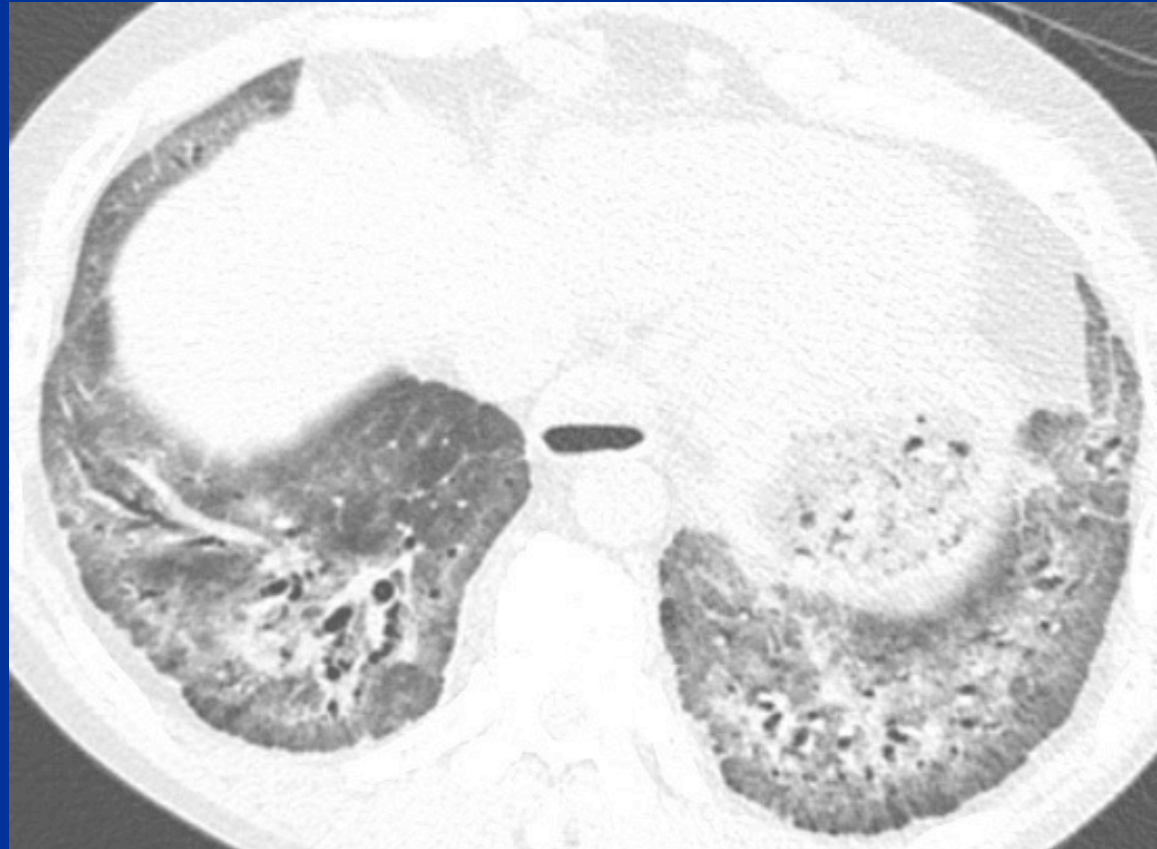
## What is the best diagnosis?

1. Aspiration
2. Diffuse pulmonary hemorrhage
3. Nonspecific interstitial pneumonitis
4. Organizing pneumonia



# Case 2 Findings

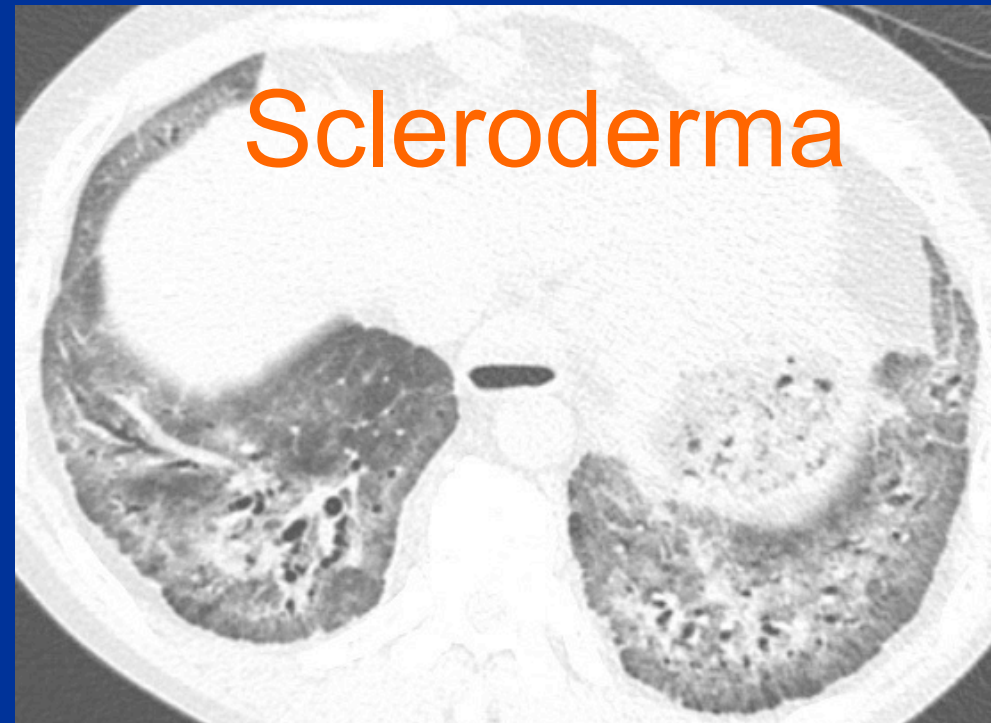- Lower and central lung fibrosis
- Relative subpleural sparing
- No honeycombing
- Esophageal dilation



# Case 2

## What is the best diagnosis?

1. Aspiration
2. Diffuse pulmonary hemorrhage
3. Nonspecific interstitial pneumonitis
4. Organizing pneumonia

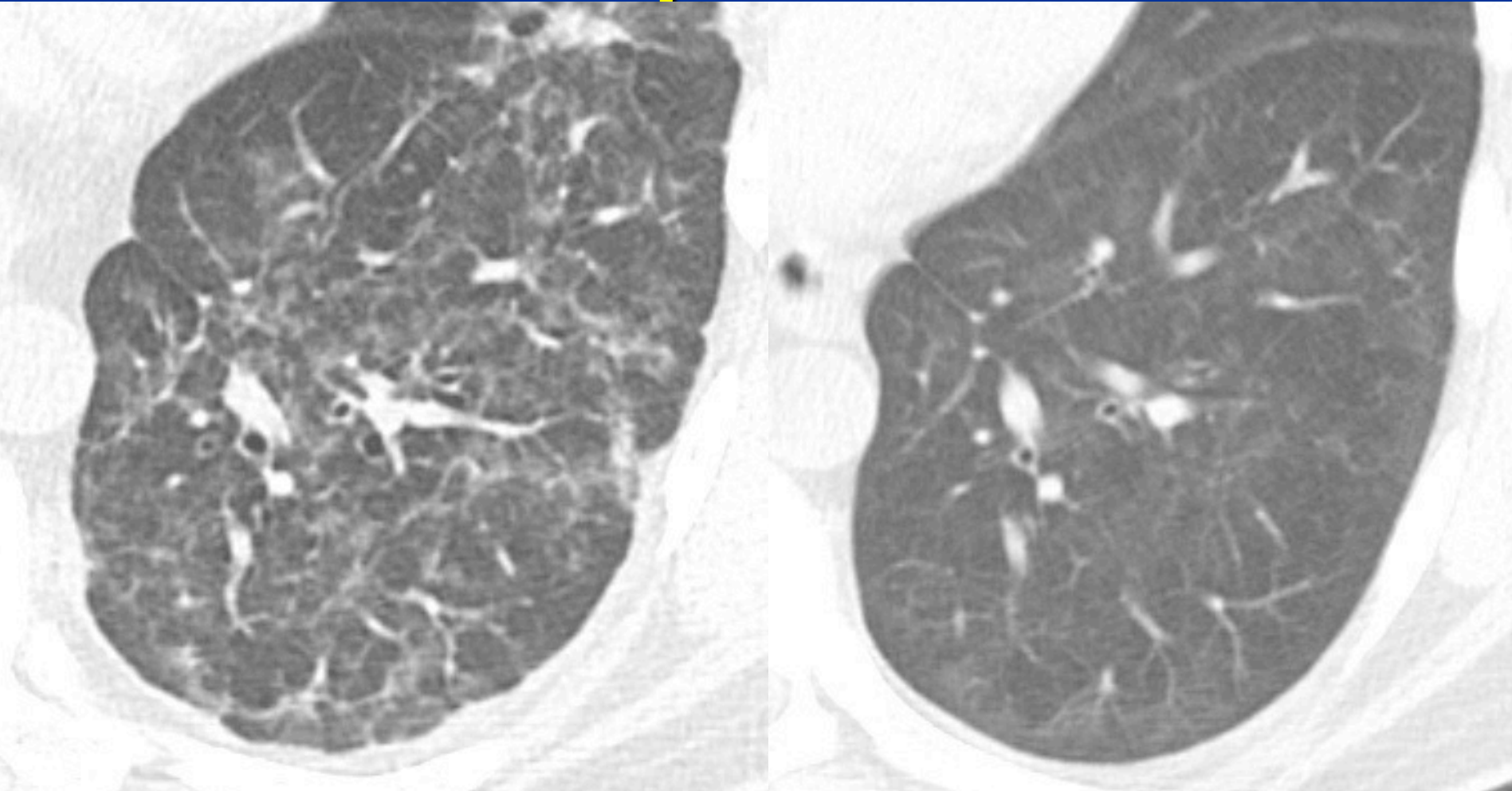


# Case 2 Differential Diagnosis

## Peribronchovascular fibrosis

1. Aspiration (mimic)
2. Diffuse pulmonary hemorrhage
3. Nonspecific interstitial  
pneumonitis
4. Organizing pneumonia

# Case 2 Differential Aspiration



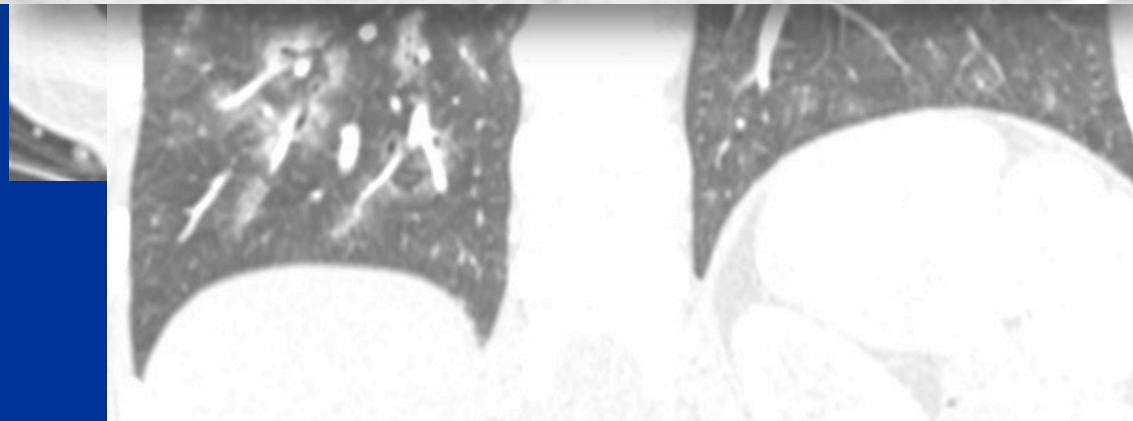
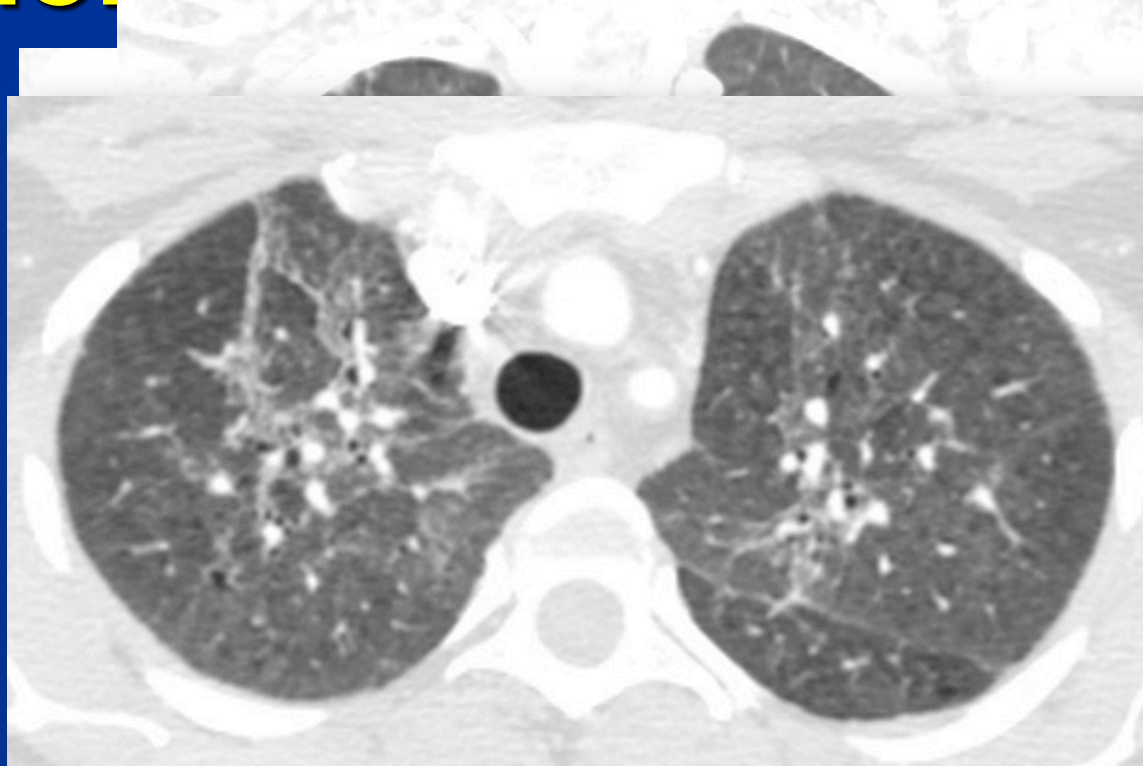
bronchial  
dilation



# Case 2 Differential

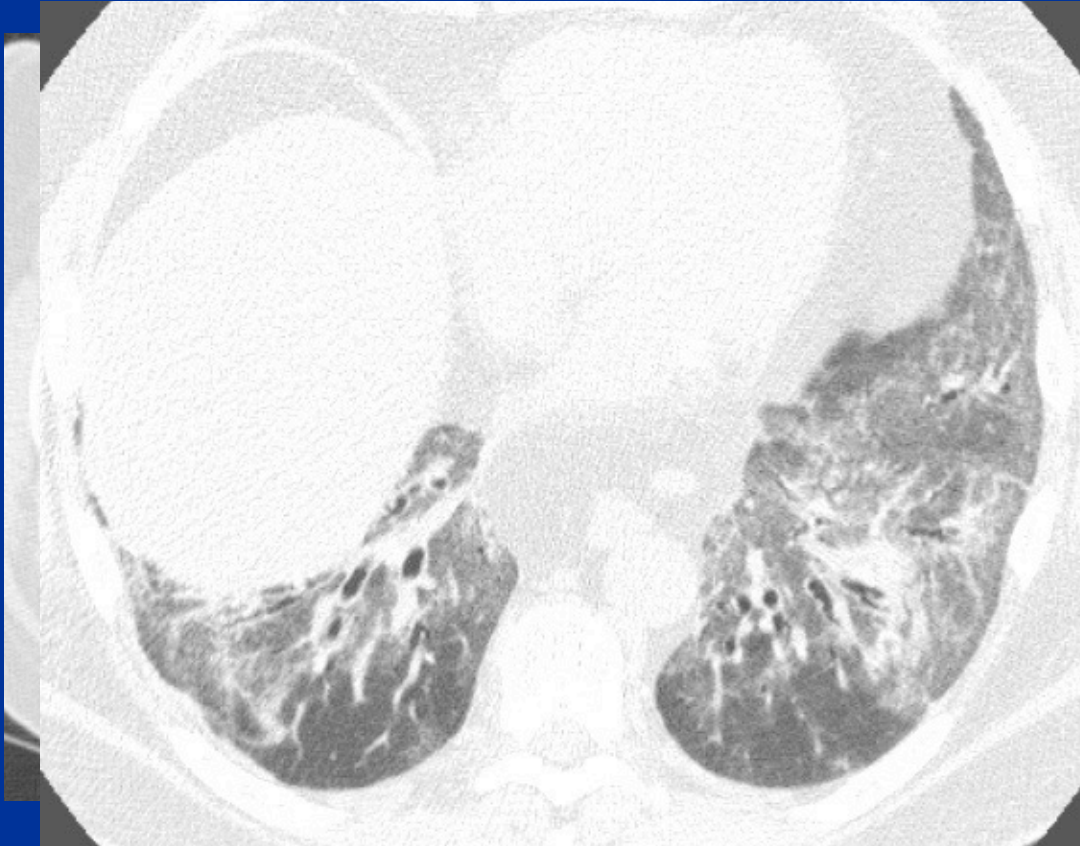## Diffuse pulmonary hemorrhage

- Ground-glass or consolidation
- Spares lung periphery
- May progress to fibrosis if chronic/recurrent



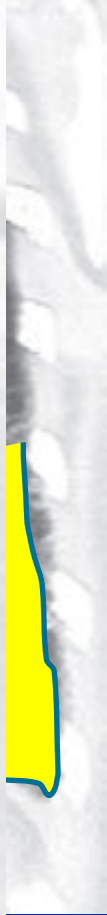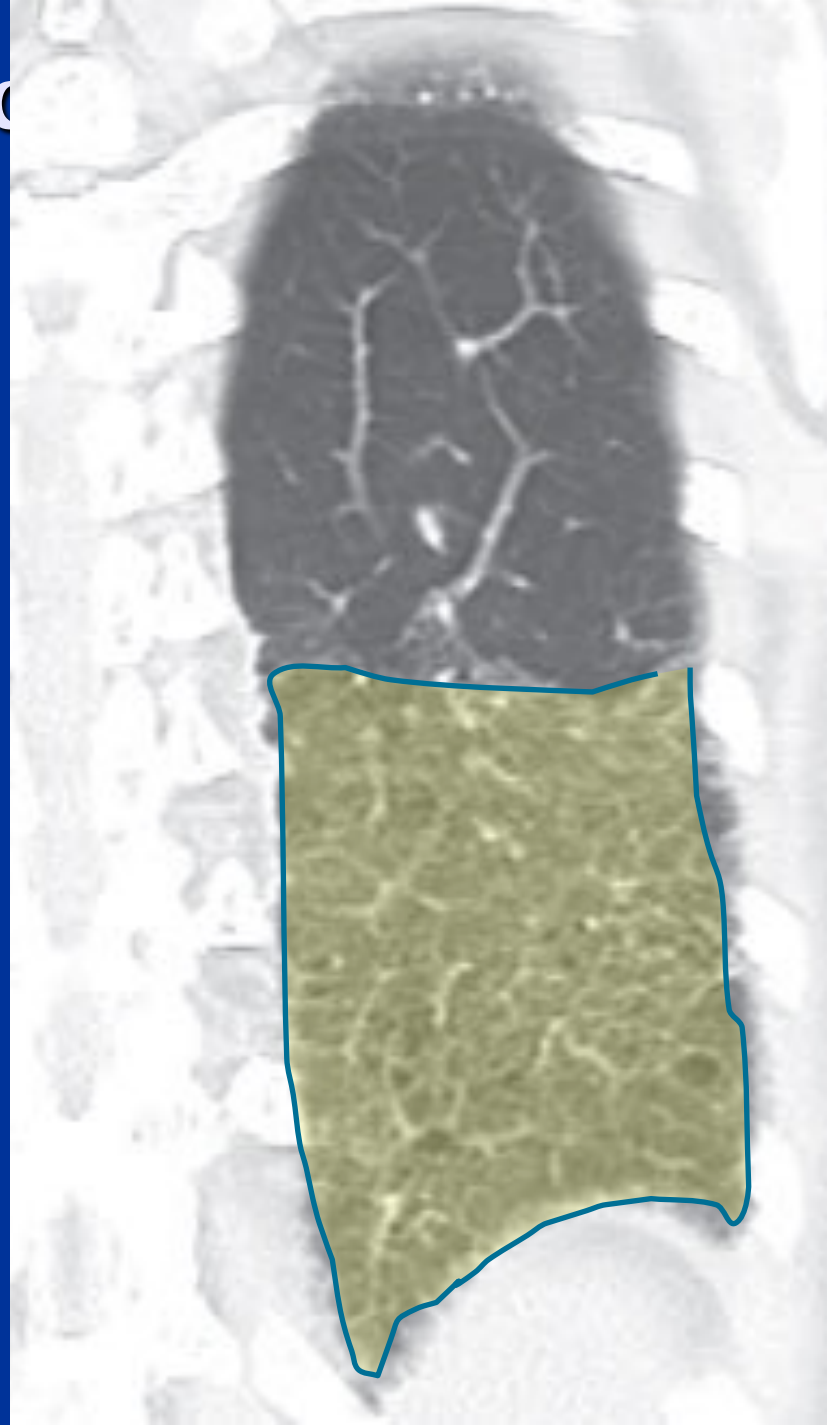
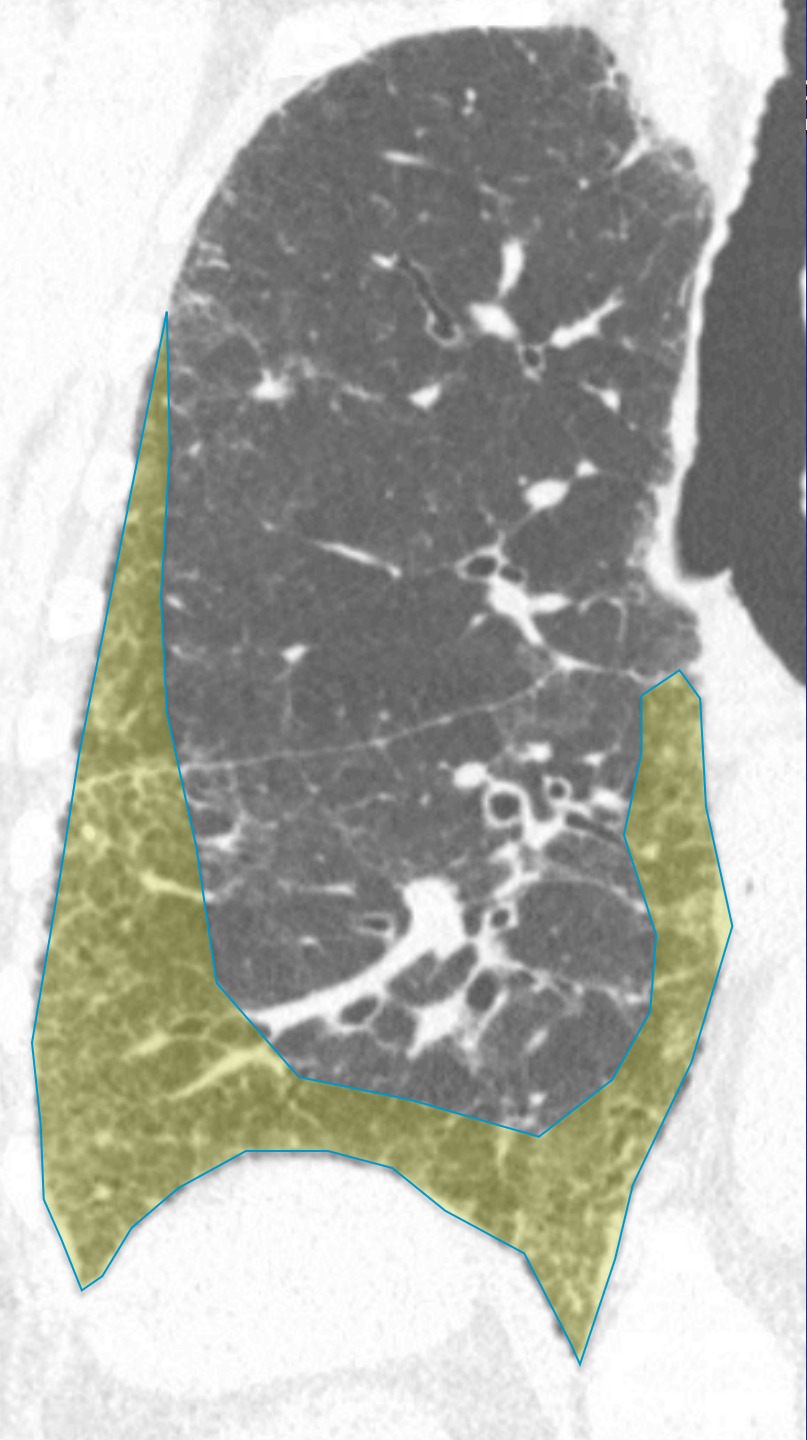
# Case 2 Differential NSIP

- Ground-glass and reticulation
- Basilar
- Peripheral sparing highly suggestive
  - Majority dif or peripheral

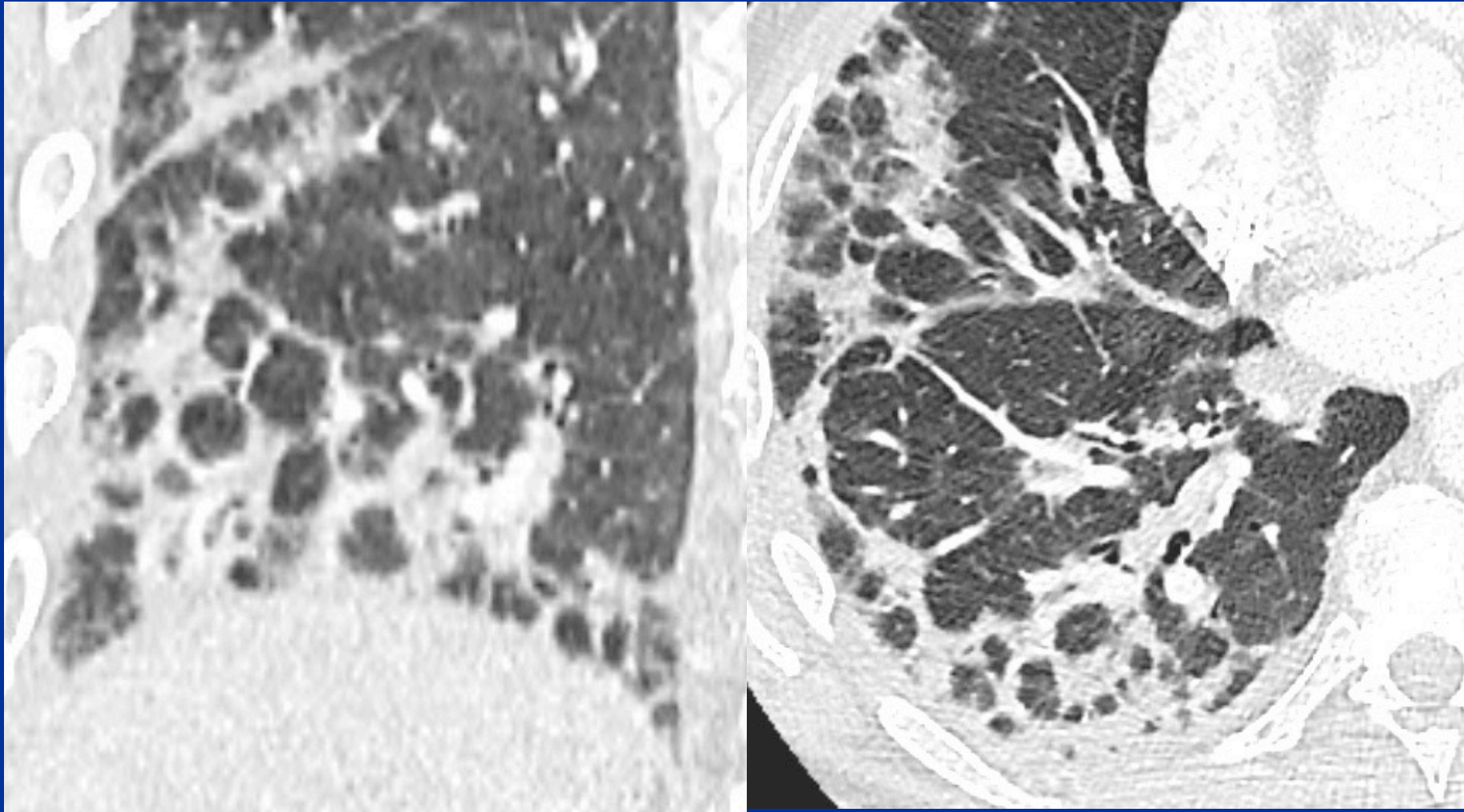




ec

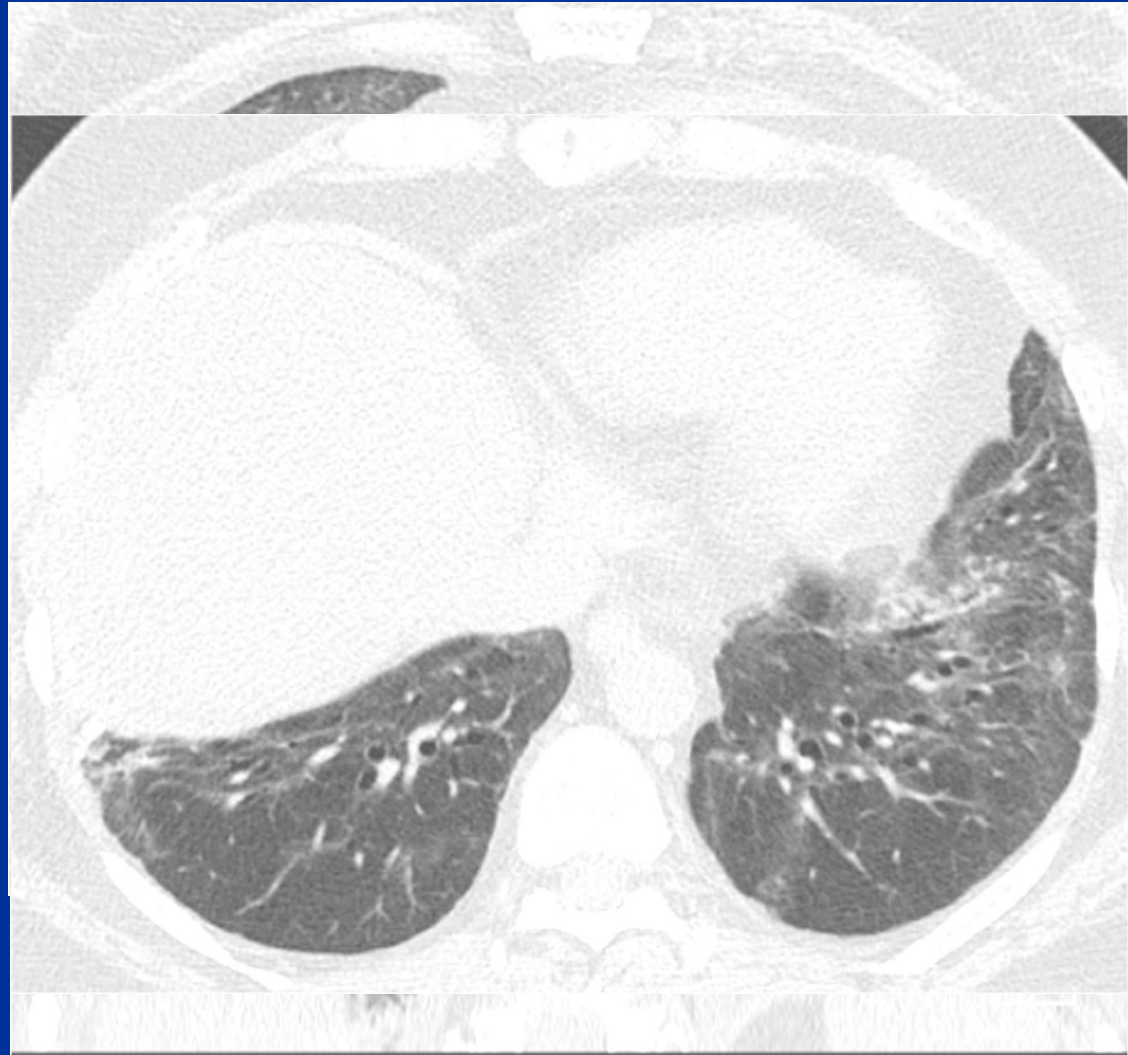

# Case 2 Differential Organizing pneumonia



# Case 3 History

- 45-year-old man with arthralgia and dyspnea

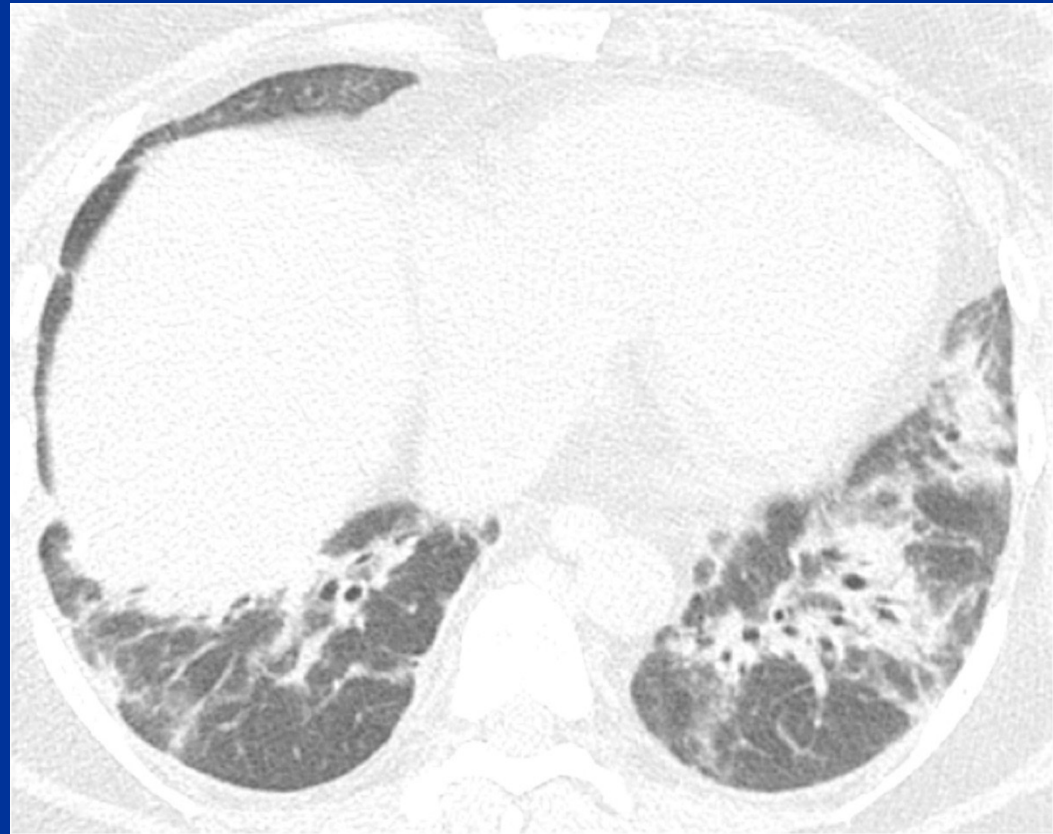



# Case 3

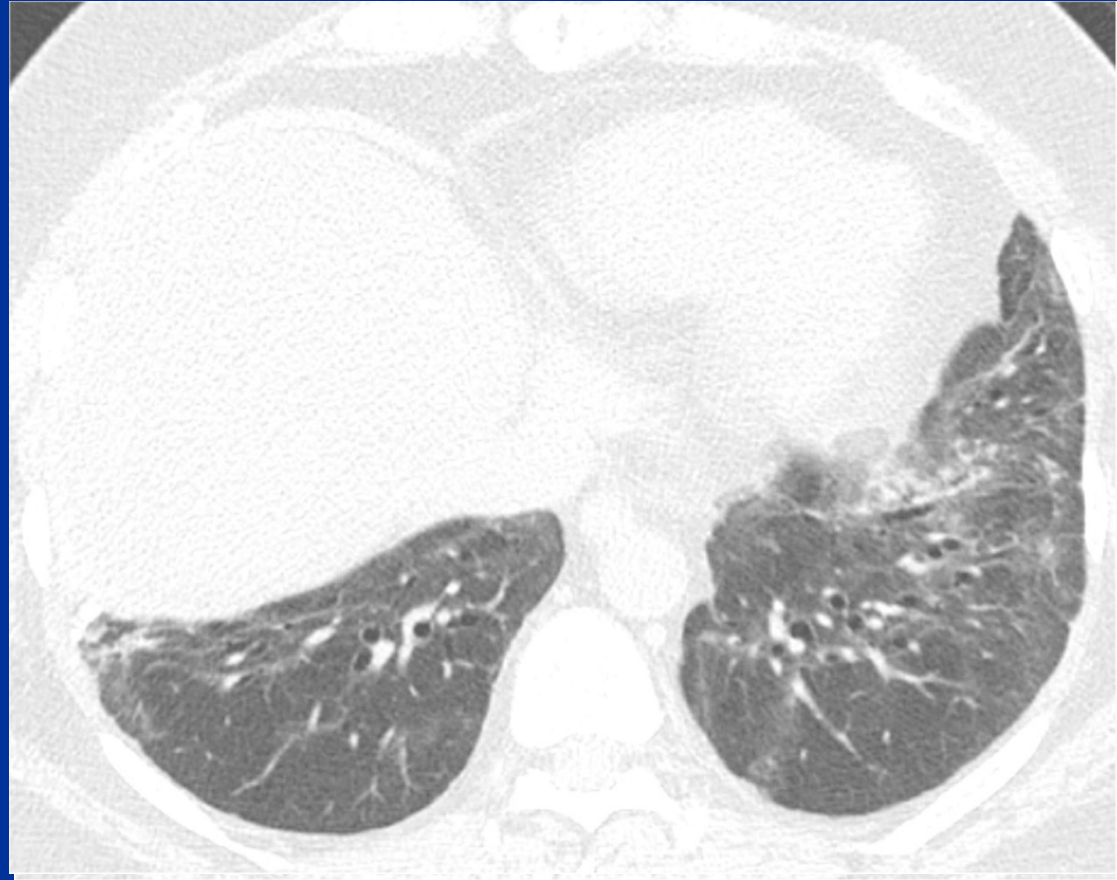
## What is the best diagnosis?

1. Dermatomyositis, polymyositis
2. Rheumatoid arthritis
3. Scleroderma
4. Systemic lupus erythematosus



# Case 3 Findings

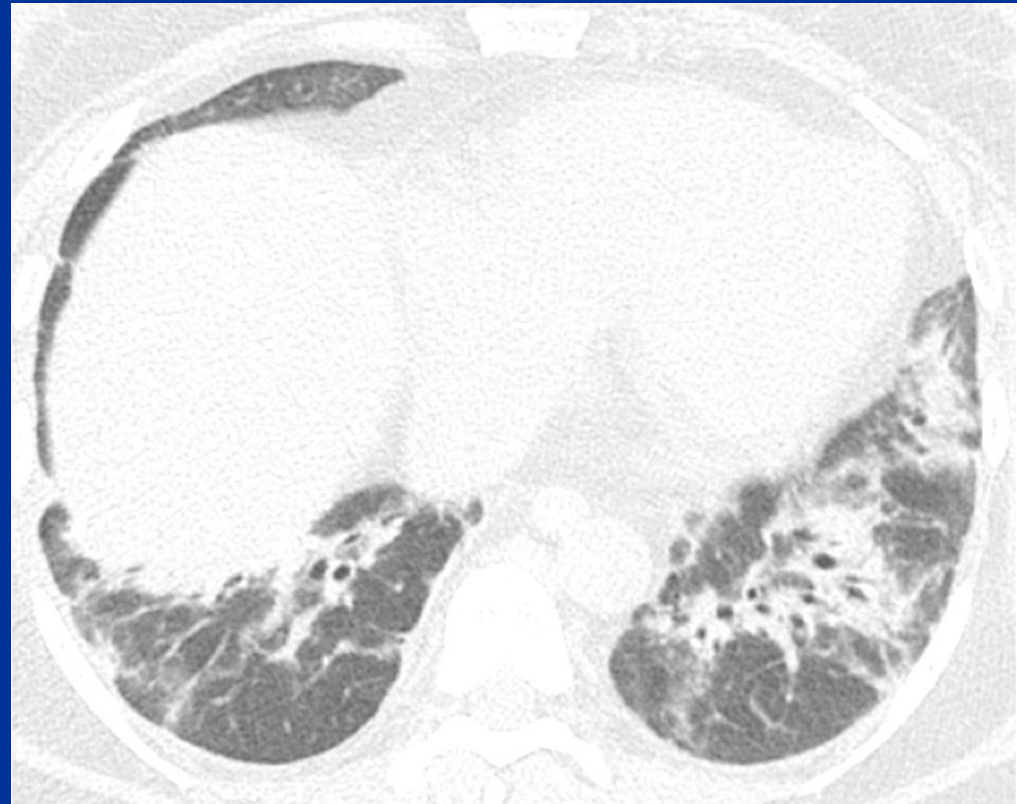- Central lung consolidation
- Rapidly clears with steroids
- Mild residual GGO, reticulation, and bronchial dilation



# Case 3

## What is the best diagnosis?

1. Dermatomyositis, polymyositis
2. Rheumatoid arthritis
3. Scleroderma
4. Systemic lupus erythematosus



# Case 3 Differential Diagnosis

## Connective tissue disease

1. Dermatomyositis, polymyositis
2. Mixed CTD
3. Rheumatoid arthritis
4. Scleroderma
5. Sjögren syndrome
6. Systemic lupus erythematosus
7. IPAF



# Case 3 Differential Diagnosis

## Connective tissue disease

1. Dermatomyositis, polymyositis
2. Mixed CTD
3. Rheumatoid arthritis
4. Scleroderma
5. Sjögren syndrome
6. Systemic lupus erythematosus
7. IPAF

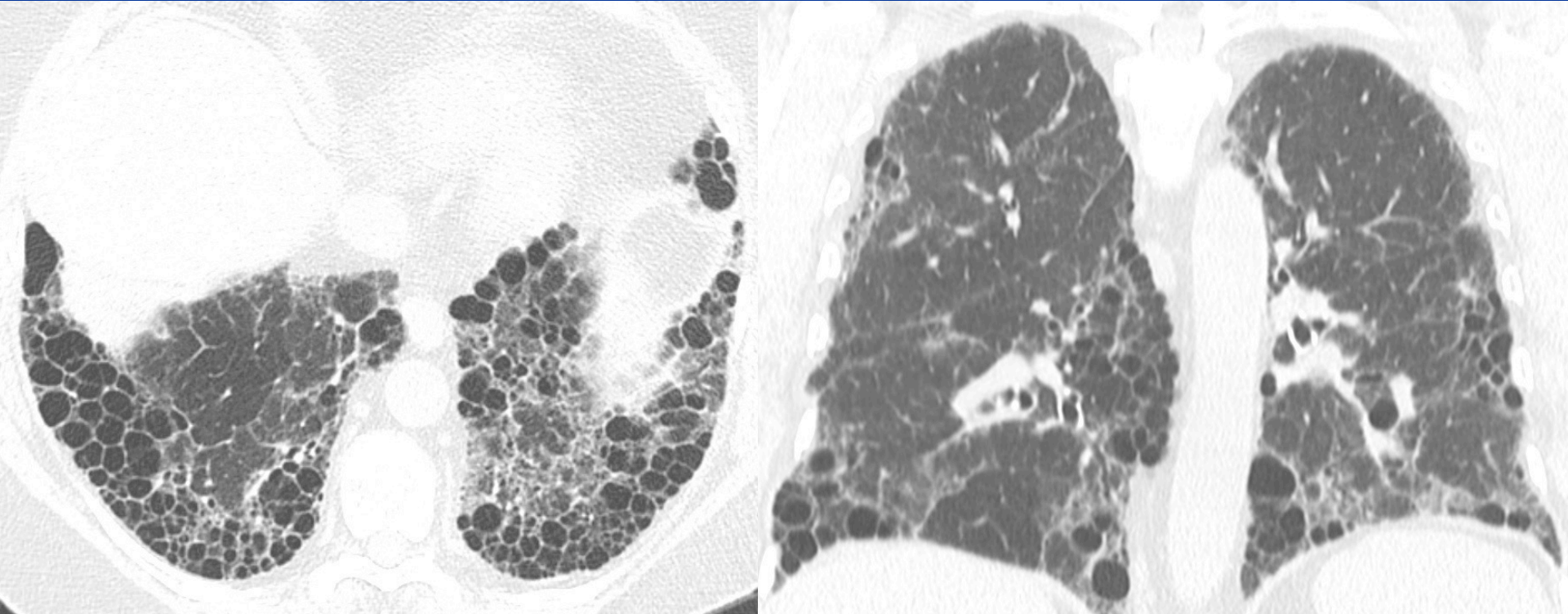
# Case 3 Differential Diagnosis

## Collagen vascular disease

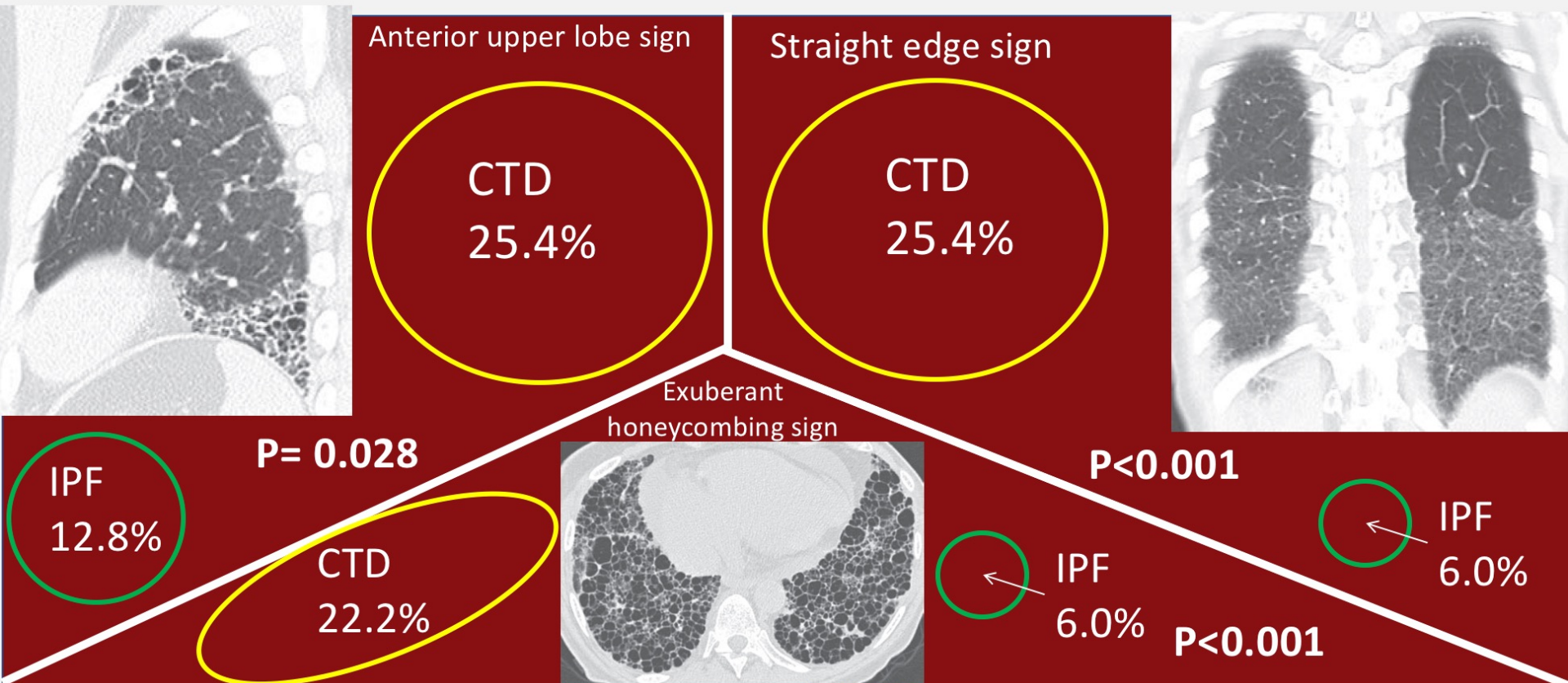
Patterns	RA	Scleroderma	PM/DM	Sjögren
<b>UIP</b>	++	++	+	+
<b>NSIP</b>	+	++++	++	+
<b>OP</b>	++	+	++	-
<b>OB</b>	++	-	-	-
<b>Bronchiectasis</b>	++	-	-	++
<b>LIP</b>	-	-	-	+++

Adapted from Lynch DA. JTI. 2009.

# RA UIP



# CT Features of the Usual Interstitial Pneumonia Pattern: Differentiating Connective Tissue Disease–Associated Interstitial Lung Disease From Idiopathic Pulmonary Fibrosis



Chung JH, et al. 2018 Feb;210(2):307-313.

**AJR**

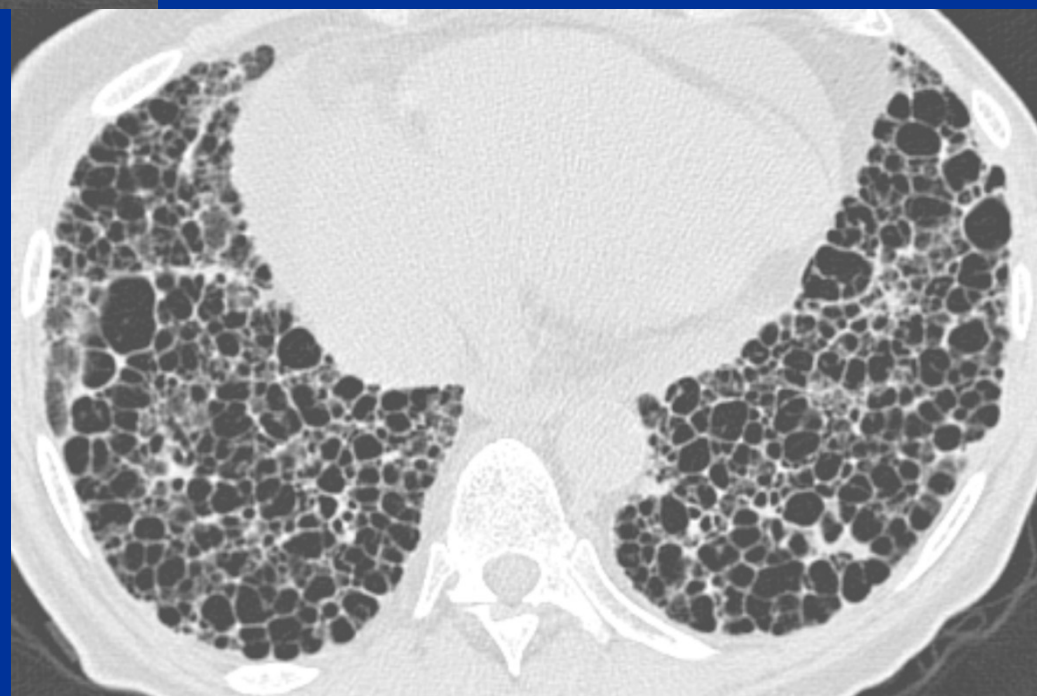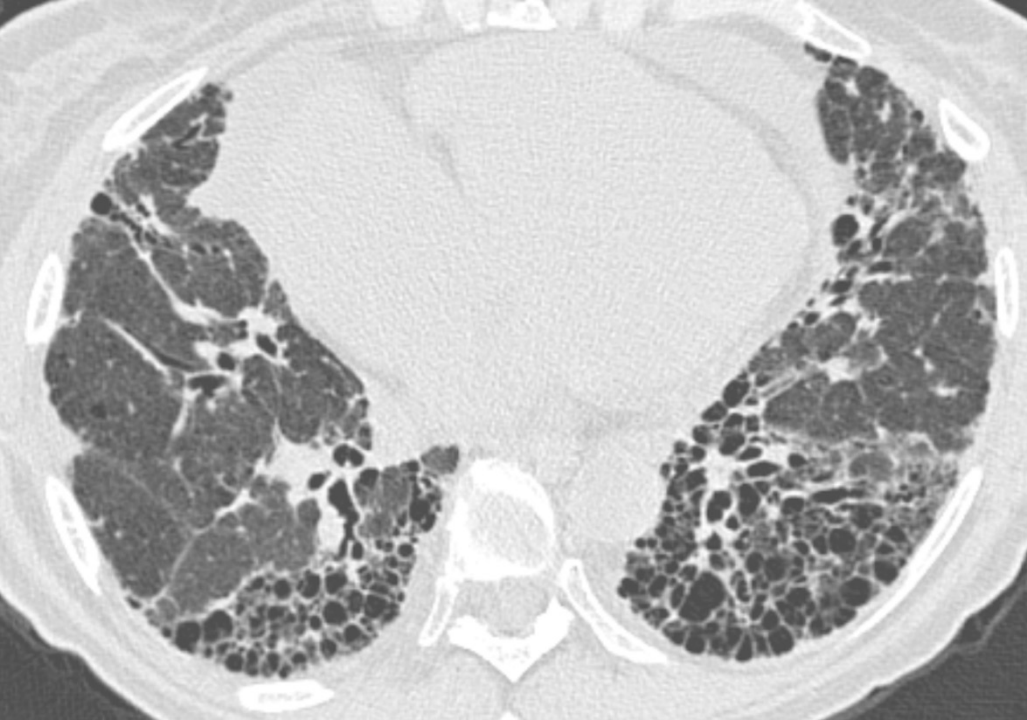*American Journal of Roentgenology*

Diagnostic Imaging and Related Sciences

Any CT sign	19.5 (26)	42.9 (27)	42.9	80.5	2.19	0.71	< 0.001
-------------	-----------	-----------	------	------	------	------	---------

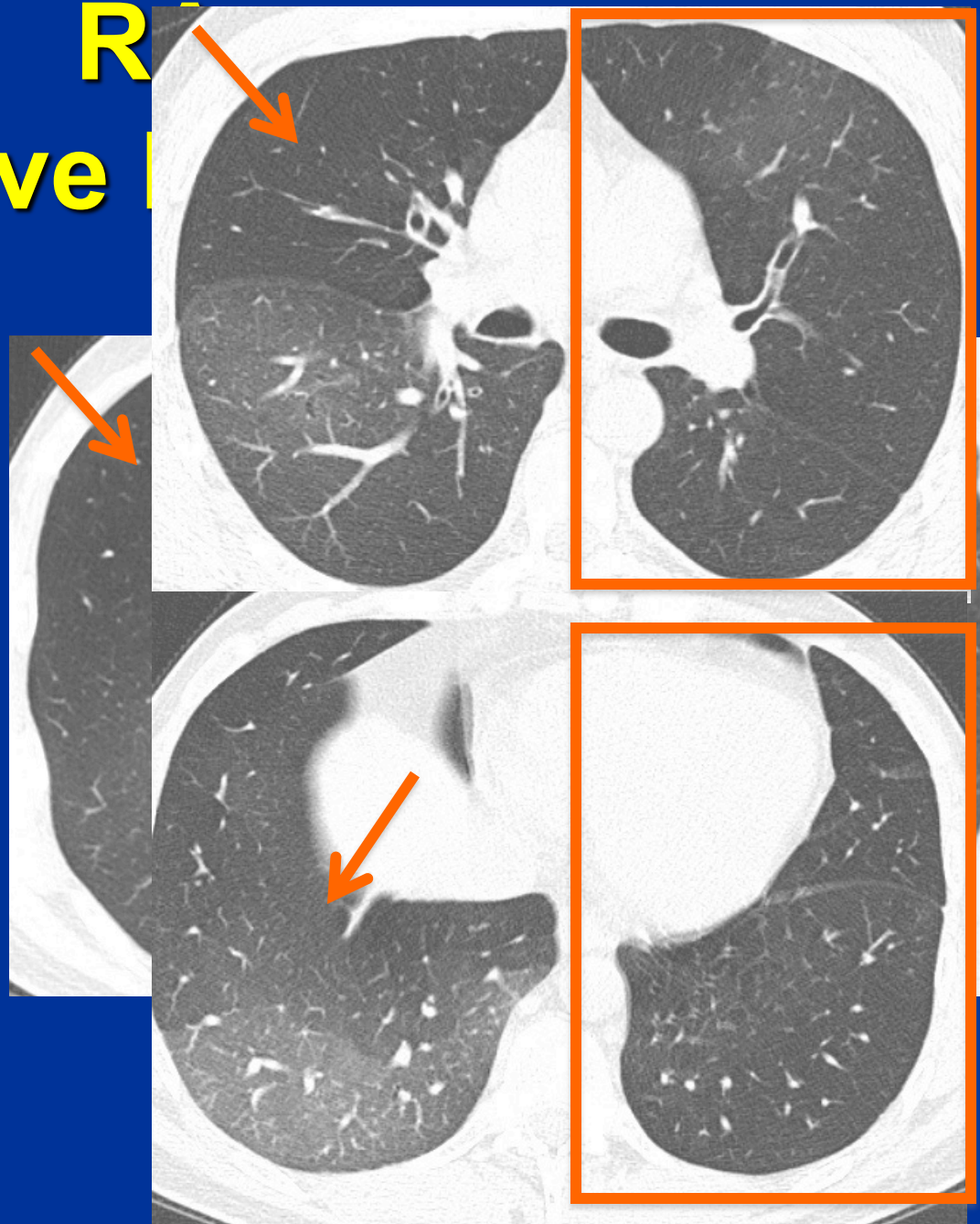
Note—Values in parentheses are number of subjects.  
<sup>a</sup>Statistically significant





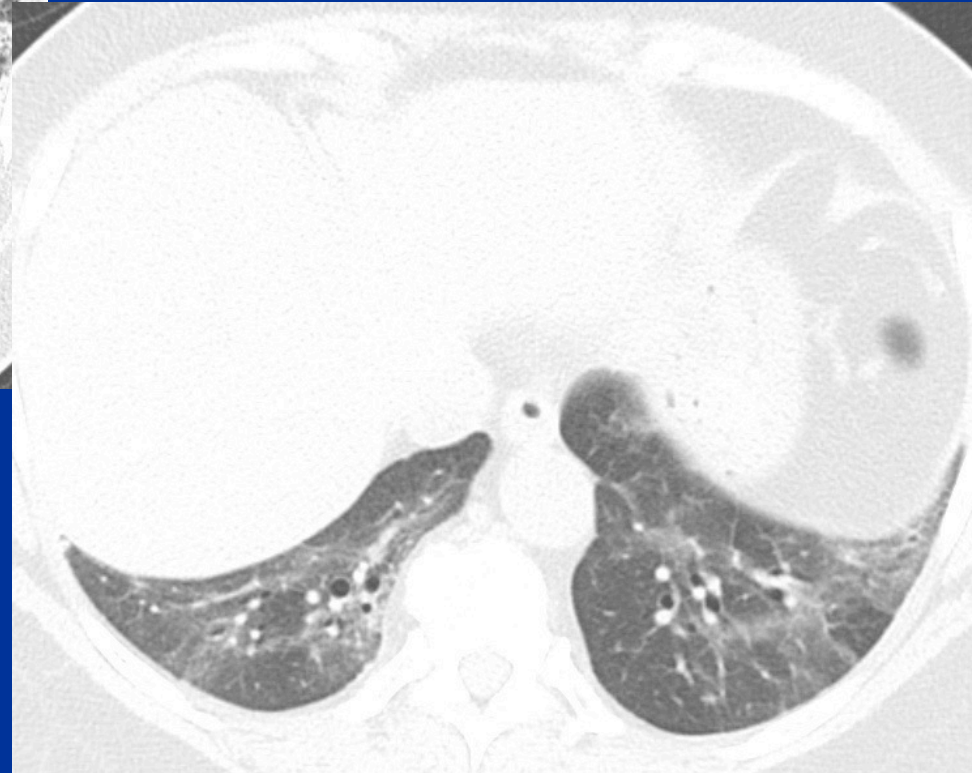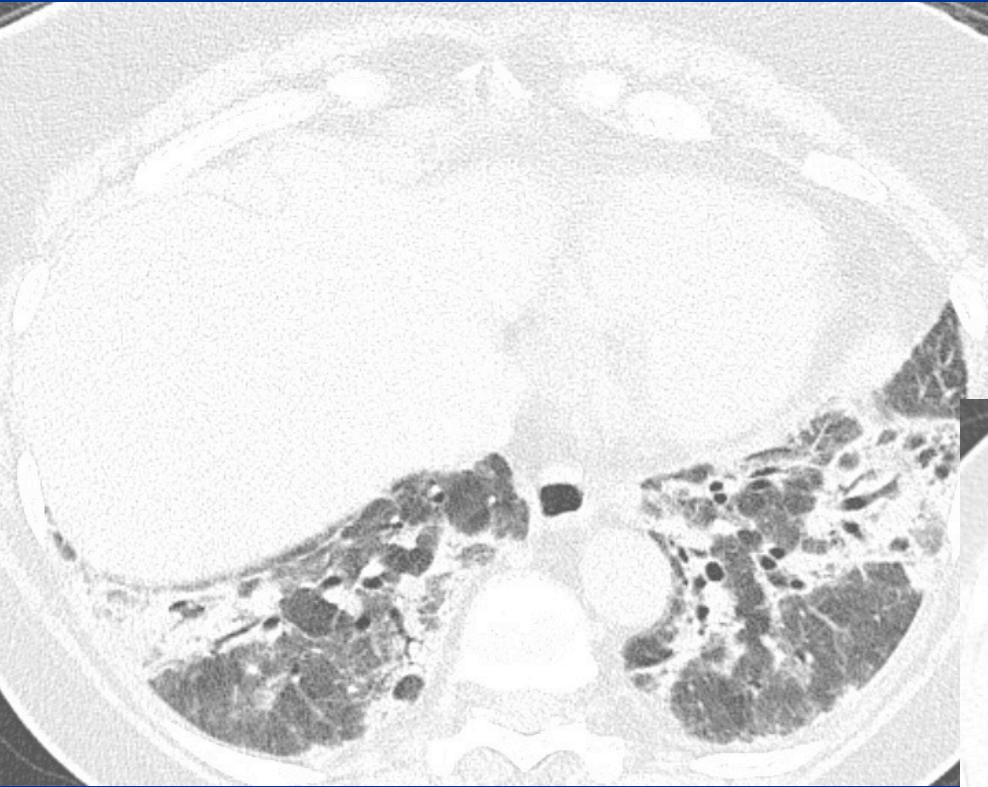
# R Obliterative

- Air-trapping/
- Mosaic  
attenuation
- Bronchial wall thickening and dilation



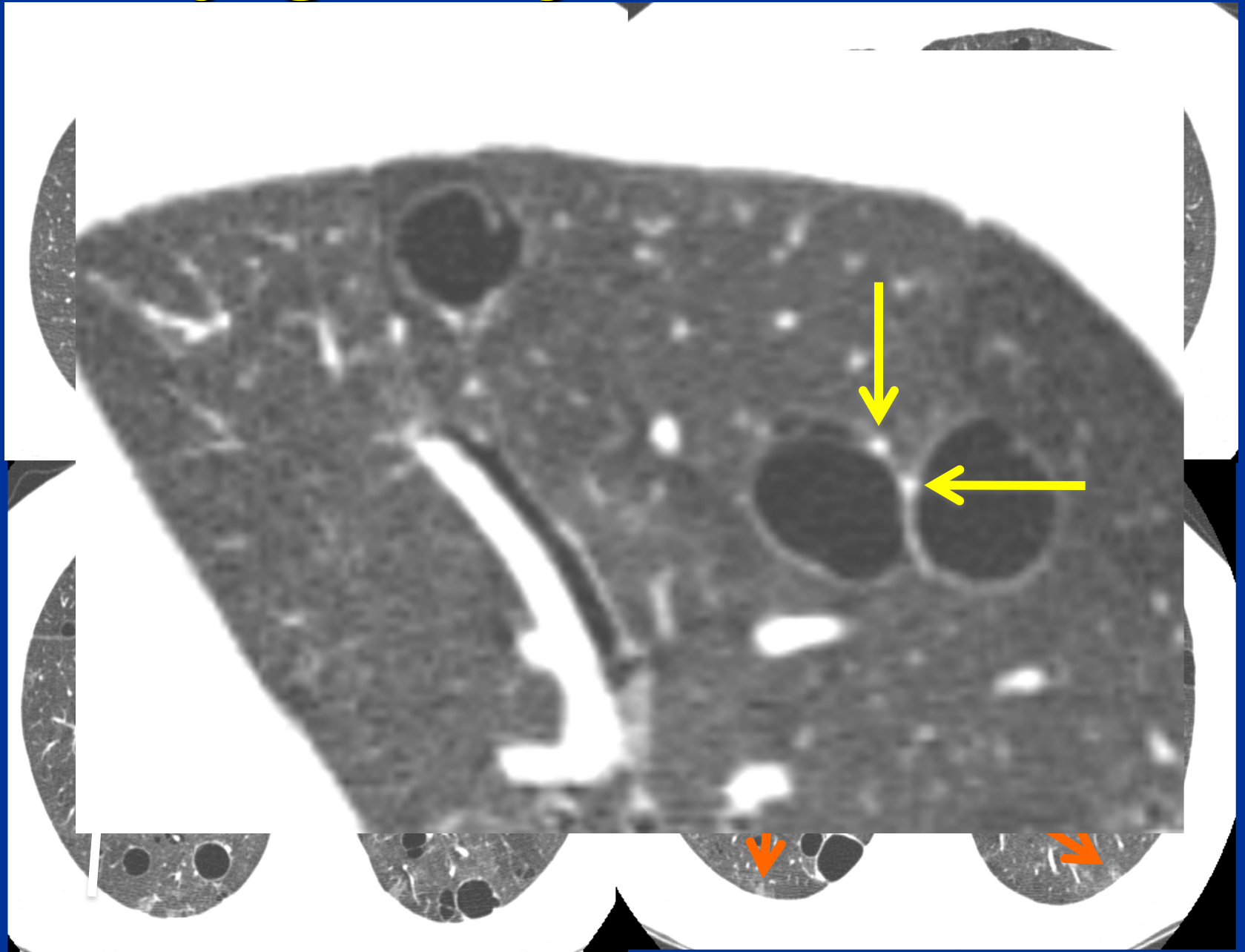
# DM/PM

## NSIP and OP



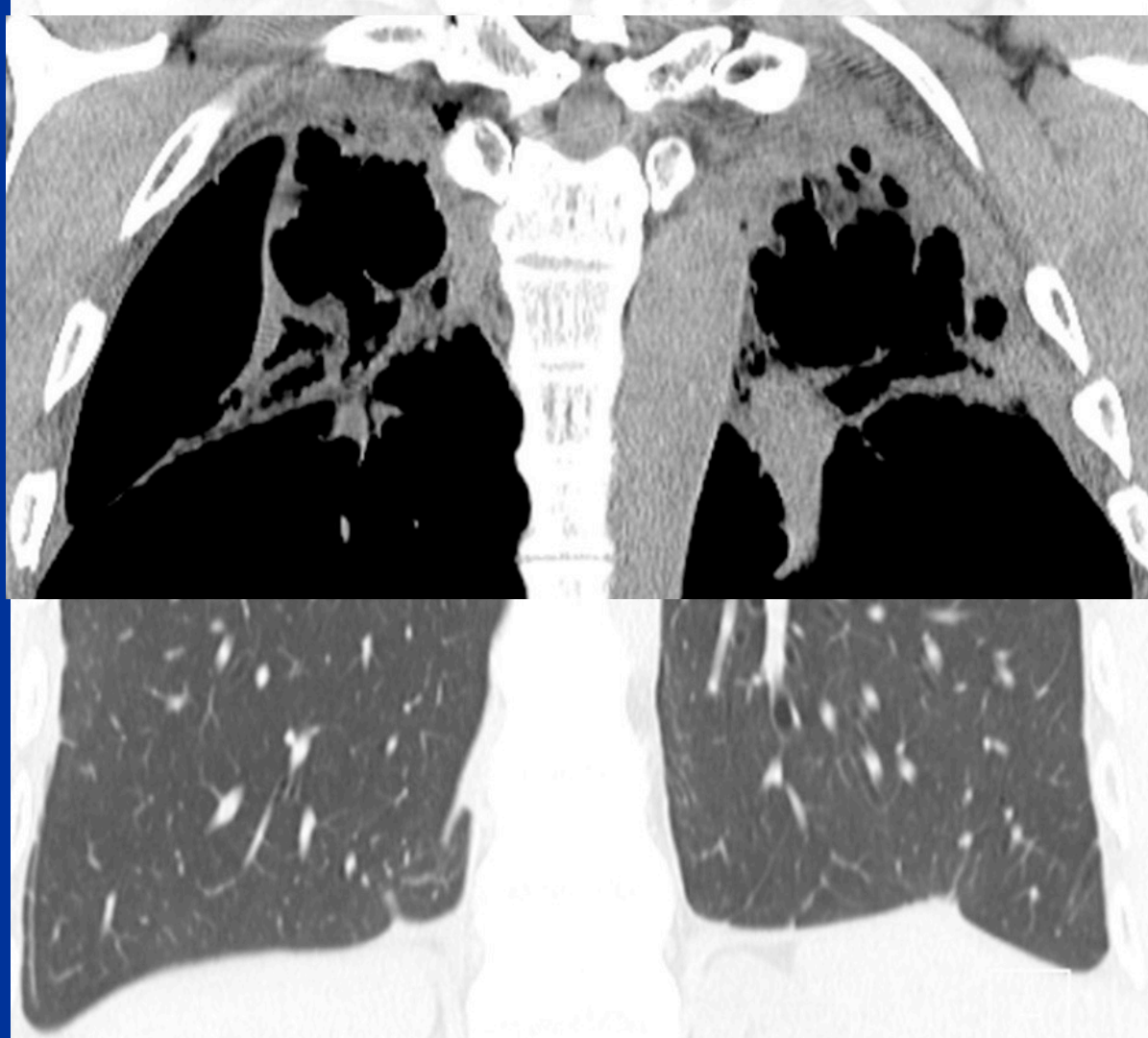


# Sjögren syndrome: LIP



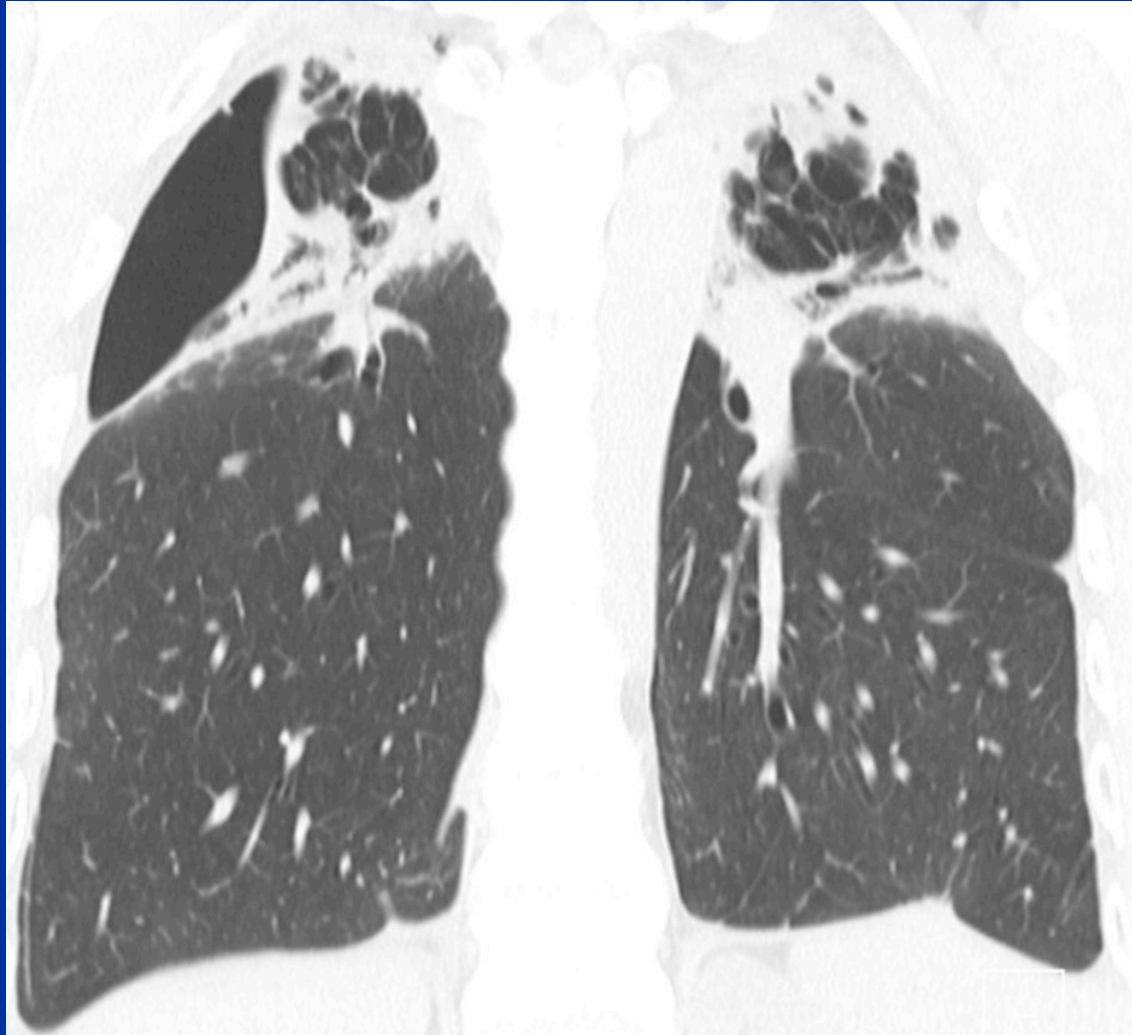
# Case 4 History

- 43-year-old man with dyspnea and hypoxia



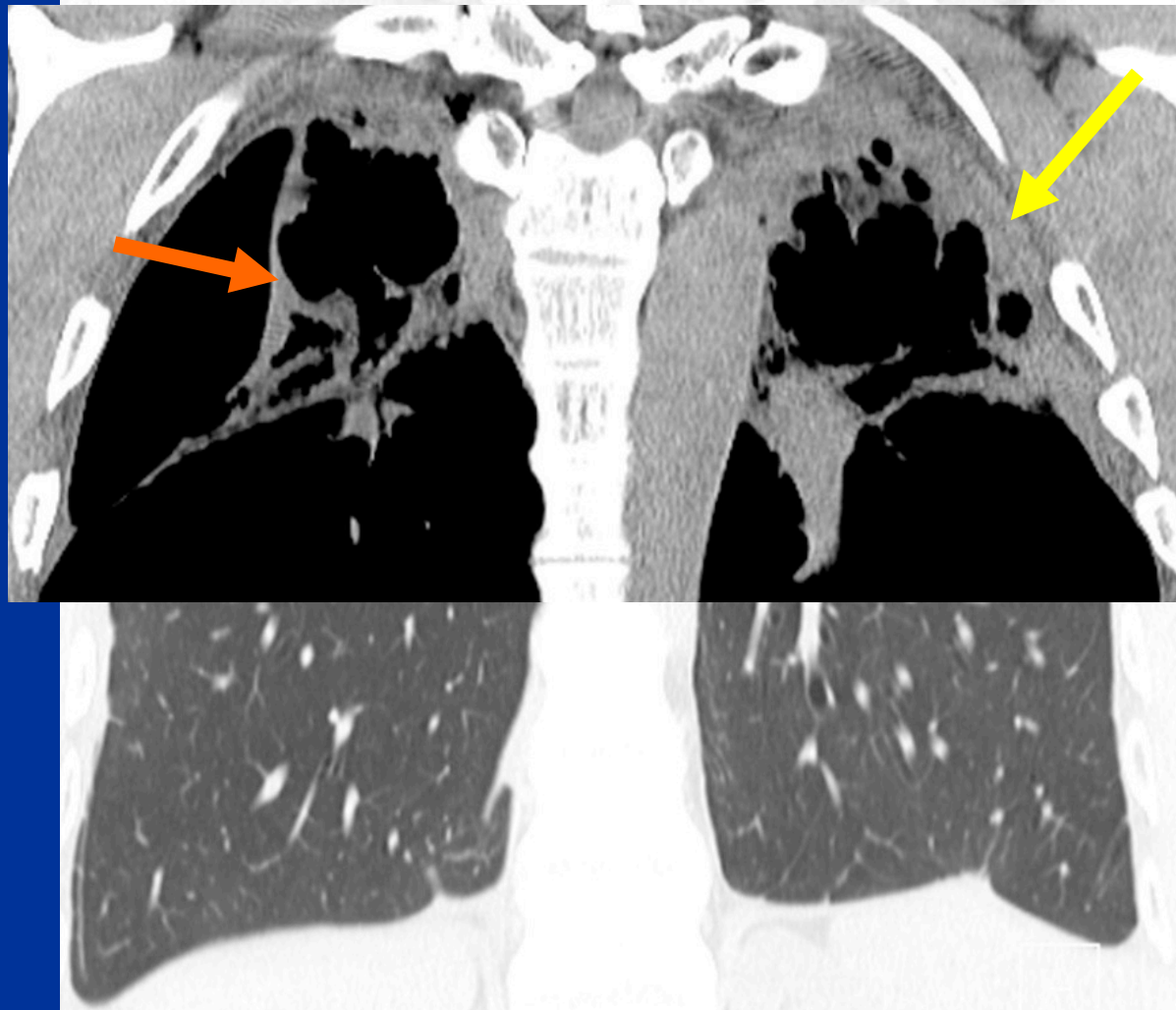
# Case 4

What is the best diagnosis?



# Case 4 Findings

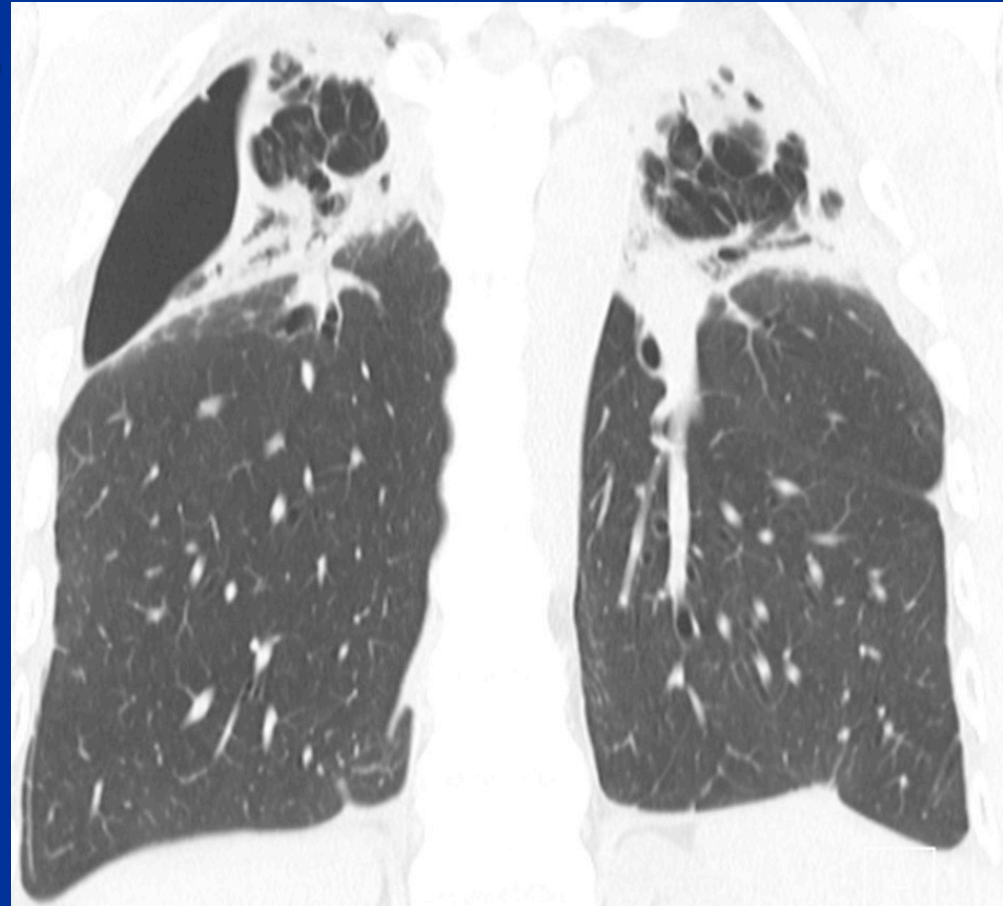
- Upper lung fibrosis
- Extensive pleural and subpleural fibrosis



# Case 4

## What is the best diagnosis?

1. Desquamative interstitial pneumonitis
2. Idiopathic pleuroparenchymal fibroelastosis
3. Nonspecific interstitial pneumonitis
4. Usual interstitial pneumonitis





# Case 4 Differential Diagnosis

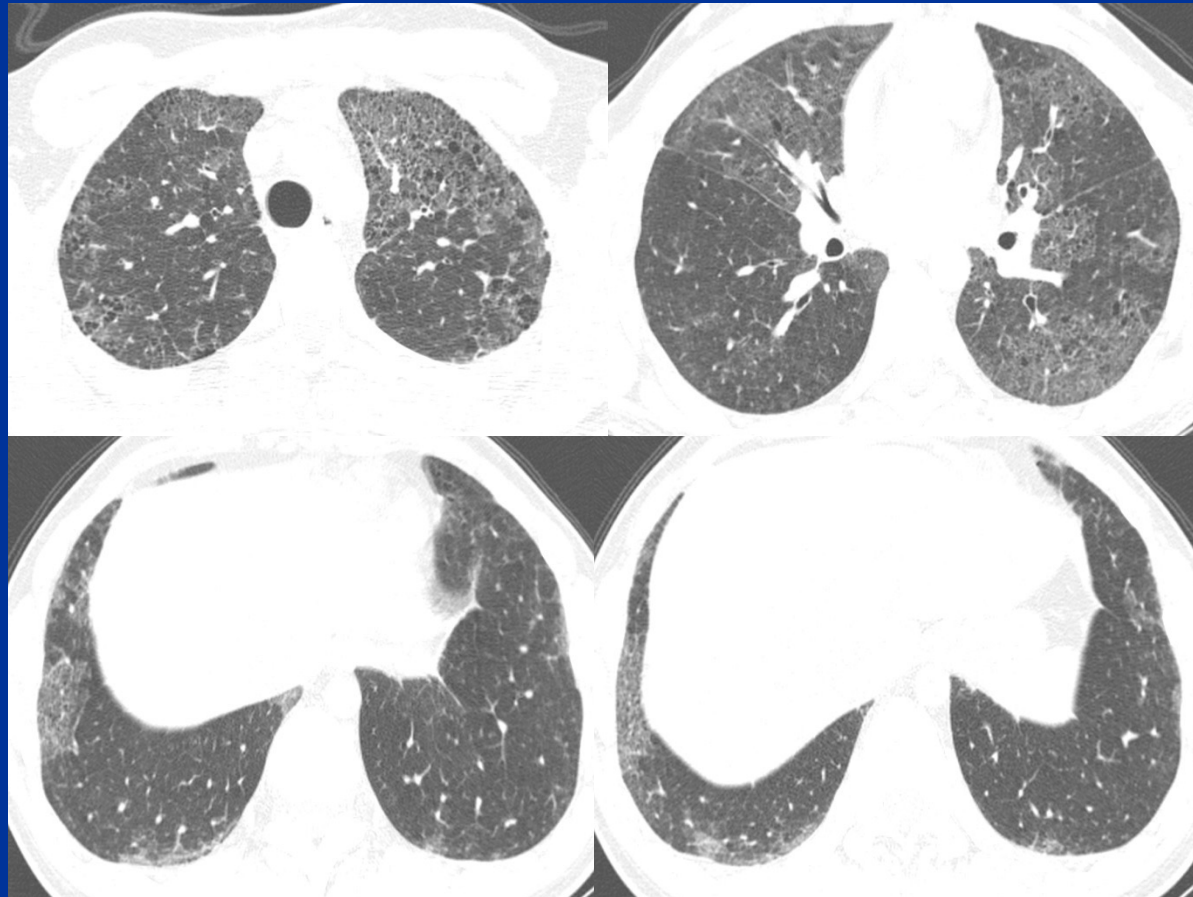
## Upper lung fibrosis

1. Familial pulmonary fibrosis
2. Hypersensitivity pneumonitis
3. Idiopathic pleuroparenchymal fibroelastosis
4. Sarcoidosis
5. Silicosis/Coal Worker's

# Case 4 Differential

## Familial pulmonary fibrosis

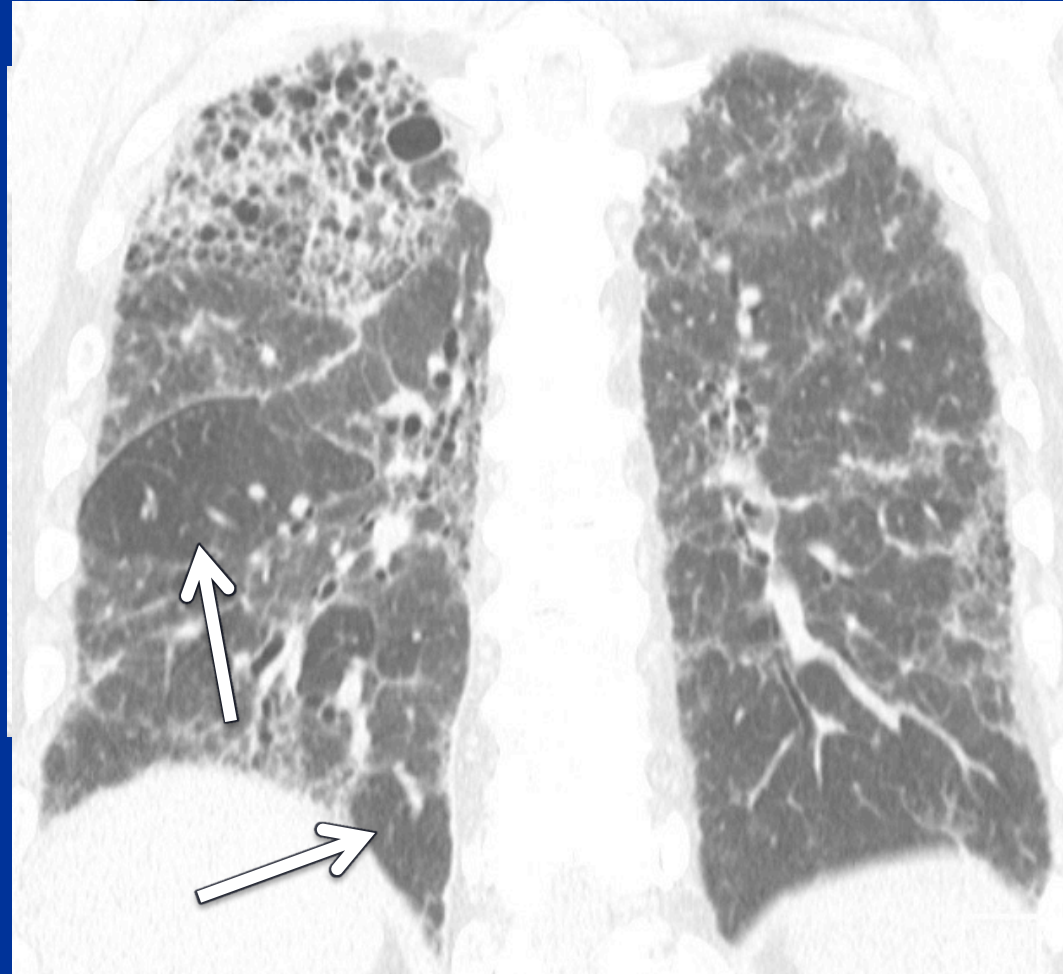
- Upper and diffuse zonal
- Less commonly axially peripheral (67% compared to >90% for UIP/IPF)



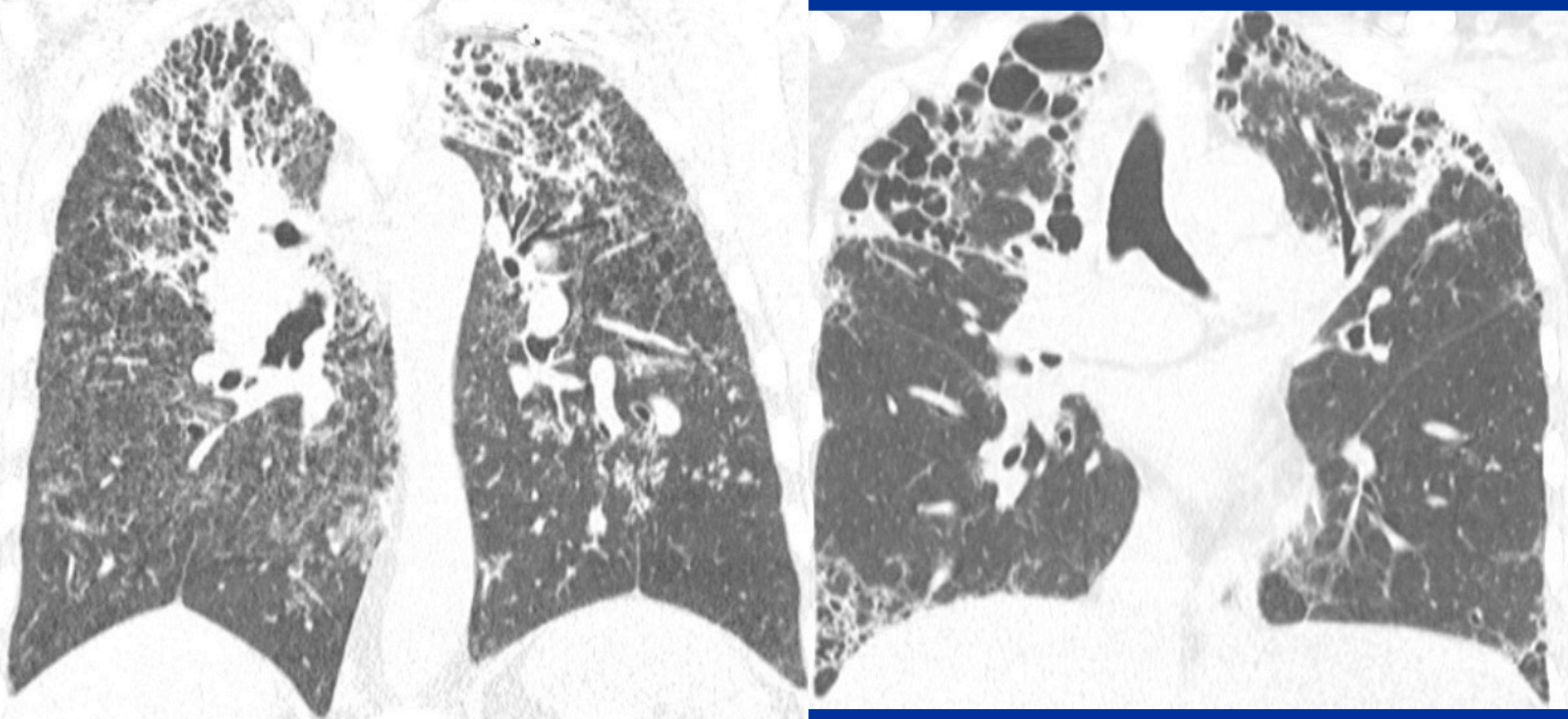
# Case 4 Differential

## Hypersensitivity pneumonitis

- Ground-glass
  - CLO, patchy, diffuse
- Upper lung fibrosis
- Air-trapping
- Exposure history



# Case 4 Differential Sarcoidosis

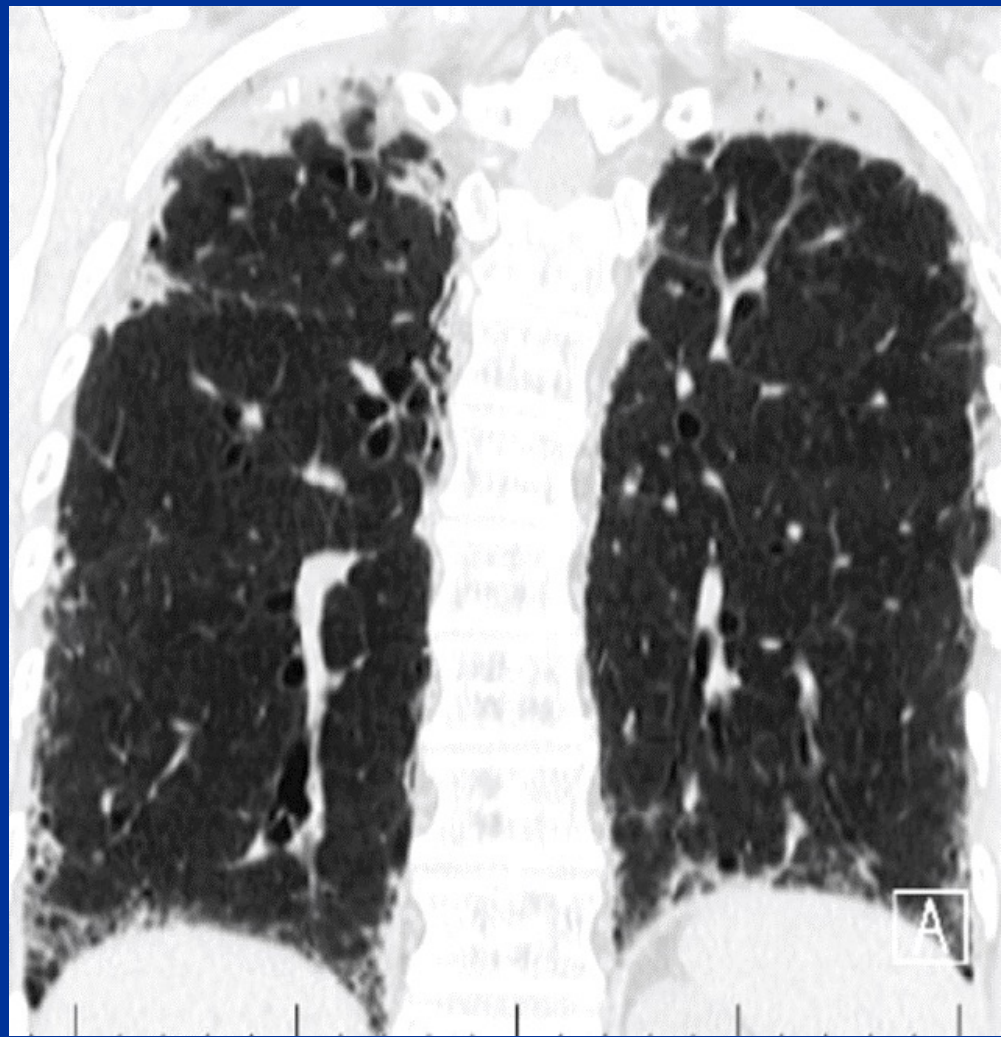




# Case 4 Differential

## Pleuroparenchymal fibroelastosis

- Extensive UL subpleural and pleural fibrosis
  - Basal fibrosis not uncommon
- Progressive; may worsen rapidly.
  - Biopsy instigator
- Related to recurrent infection, CTD, chemo, HSCT, lung transplant







Thank You  
Follow me on Twitter:  
 @jonherochung



THE UNIVERSITY OF  
**CHICAGO**  
MEDICINE